

## Morphologic and Hemodynamic Consequences After Percutaneous Balloon Valvotomy for Neonatal Pulmonary Stenosis: Medium-Term Follow-Up

HUSSEIN TABATABAEI, MD, CHRISTINE BOUTIN, MD, FRCPC,  
DAVID G. NYKANEN, MD, FRCPC, ROBERT M. FREEDOM, MD, FRCPC, FACC,  
LEE N. BENSON, MD, FRCPC, FACC

Toronto, Ontario, Canada

**Objectives.** This study sought to evaluate ventricular and valvular morphologic changes, hemodynamic consequences and clinical outcomes of pulmonary balloon valvotomy performed in the neonatal period.

**Background.** Previous studies support percutaneous balloon valvotomy as the management option of choice for infants and children with valvular pulmonary stenosis. Less information is available to define the impact of valvotomy on the clinical course when performed in the neonatal period.

**Methods.** Patient records, catheterization data, cineangiograms and selected echocardiograms (initial and most recent studies) of 37 consecutive neonates undergoing attempted balloon dilation were reviewed.

**Results.** Dilation was accomplished in 35 (94%) of 37 attempts. Immediately after dilation, the transvalvular peak to peak systolic gradient decreased from  $60 \pm 22$  mm Hg (mean  $\pm$  SD, range 20 to 100) to  $11 \pm 10$  mm Hg (range 0 to 45) ( $p < 0.0001$ ), and the right ventricular/aortic systolic pressure ratio decreased from  $1.25 \pm 0.43$  (range 0.5 to 2.6) to  $0.66 \pm 0.22$  (range 0.2 to 1) ( $p <$

$0.0001$ ). Oxygen saturation measured by percutaneous oximetry increased from  $80 \pm 7\%$  to  $92 \pm 4\%$  ( $p < 0.0001$ ). Three patients died (8%), and two required repeat balloon dilation. At the follow-up visit (median 31 months, range 6 months to 8 years), the estimated peak instantaneous Doppler gradient was  $15 \pm 9$  mm Hg (range 6 to 36). Thickening of valve leaflets, initially present in 93% of patients, was found in only 4%, and leaflet mobility improved in all. Hypoplasia of the right ventricle, initially present in 31%, was found in only 4% at the latest evaluation. Pulmonary annulus diameter Z score increased from  $-3 \pm 1.0$  to  $0 \pm 0.1$  ( $p < 0.0001$ ). Freedom from reintervention was 90%, 84% and 84% at 1, 2 and 8 years, respectively.

**Conclusions.** These data support the application of balloon valvotomy as the initial intervention in the treatment algorithm for neonates with critical pulmonary valve stenosis. Medium-term follow-up observations demonstrate sustained hemodynamic relief and support maturation of the right ventricle and pulmonary valve annulus, with the expectation of a good long-term outcome.

(*J Am Coll Cardiol* 1996;27:473-8)

Previous work has supported percutaneous pulmonary balloon valvotomy as the treatment of choice for infants, children and adults with typical valvular pulmonary stenosis (1-5). Less information, however, is available to define the impact of balloon valvotomy on clinical course and right heart morphology when performed in the neonatal period (6). This study presents medium- to long-term observations after balloon valvotomy, focusing on the hemodynamic and morphologic consequences of the balloon valvotomy when performed in the neonate.

From the University of Toronto, Faculty of Medicine, Department of Pediatrics, Division of Cardiology, The Variety Club Cardiac Catheterization Laboratories, The Hospital for Sick Children, Toronto, Ontario, Canada.

Manuscript received January 5, 1995; revised manuscript received September 19, 1995; accepted September 26, 1995.

**Address for correspondence:** Dr. Lee N. Benson, The Hospital for Sick Children, 555 University Avenue, Toronto, Ontario M5G 1X8 Canada.

### Methods

**Study patients.** From January 1, 1984 through December 31, 1993, 37 consecutive neonates (16 female, 21 male) with the diagnosis of critical pulmonary stenosis had attempted balloon valvotomy. Median age at balloon dilation was 1 week (range 1 day to 4 weeks), and median weight was 3.6 kg (range 1.9 to 5.2). Since 1984, balloon valvotomy has been attempted as the initial intervention in this population regardless of right ventricular or pulmonary valve morphology. Associated cardiac lesions were found in 21% of patients and are shown in Table 1.

**Data collection.** Patient records, catheterization data and cineangiograms were reviewed. Initial cineangiograms and selected echocardiograms (initial study before balloon valvotomy and the most recent study) were reviewed in random order with the observers (H.T., L.B., and H.T., C.B., respectively) uninformed of the outcome of the patient's valvotomy. For echocardiographic and angiographic quantitative measurements, the maximal internal diameter of the pulmonary valve

**Table 1.** Associated Anomalies

	No. (%) of Patients
ASD	1 (3%)
Dextrocardia	1 (3%)
LSVC to CS	1 (3%)
PAPVD	1 (3%)
RV-CA fistula	1 (3%)
VSD (small)	2 (6%)

ASD = atrial septal defect; CA = coronary artery; CS = coronary sinus; LSVC = left superior vena cava; PAPVD = partial anomalous pulmonary venous drainage; RV = right ventricular; VSD = ventricular septal defect.

annulus was determined during early systole at the insertion of the valve leaflets in a parasternal short-axis view and from the lateral right ventriculogram. The tricuspid valve annulus was similarly measured at ventricular end-diastole at the level of insertion of valve leaflets in the apical four-chamber view and from the lateral and cranially angled anteroposterior ventriculograms. Echocardiographic dimensions were obtained off-line from a dedicated video-replay unit (Image-Vue Nova Microsonics). Angiographic measurements were obtained with electronic calipers (Mitutoyo) using known catheter diameters for magnification correction.

The determination of right ventricular hypoplasia at the time of balloon dilation was based on an angiographic index suggested by Lewis et al. (7) and also a morphologic assessment as suggested by Gool and Lillehei (8) and Bull et al. (9). The angiographic index was calculated as the sum of the average of the tricuspid valve annulus diameters and right ventricular inlet and outlet lengths, divided by the diameter of the descending aorta at the level of diaphragm. All measurements were made at end-diastole during sinus rhythm in both cranially angled anteroposterior and lateral projections. The right ventricle was considered hypoplastic if the calculated angiographic index was  $\leq 2$  (7).

Similarly, all angiograms were reviewed to determine the presence or absence of the inlet, trabecular and infundibular portions of the right ventricular cavity. The inlet portion was defined as that part of the ventricle that incorporates the tricuspid apparatus, the trabecular portion that portion of the ventricle beyond the insertion of the papillary muscles of the tricuspid valve toward the apex, while the infundibulum is the outlet portion leading to the pulmonary valve (9). The tricuspid annulus diameter was used to assess the adequacy of the inlet, as it parallels the growth of this heart segment. Any recognizable infundibular area was considered to be present regardless of how restrictive it appeared. The trabecular cavity was recognized by its irregular outline compared with the characteristically smooth inlet and outlet portions of the ventricle. The right ventricle was considered hypoplastic if any of these three portions was anatomically or functionally missing (that is, so overgrown by hypertrophied myocardium as to be effectively absent) (9). Similar observations were applied echocardiographically: the trabecular portion was considered attenuated if it did not reach the left ventricular apex in the apical four-chamber view.

The peak instantaneous pressure gradient across the pulmonary valve was determined by pulsed and continuous Doppler interrogation recorded from high parasternal short-axis or subcostal coronal planes. The motion (in systole and diastole), thickness and presence of systolic doming of the pulmonary valve leaflets, presence of supra-annular narrowing and post-stenotic dilation of main pulmonary artery were also noted echocardiographically. Similar observations were obtained angiographically from the lateral and cranially angled anteroposterior projections from the right ventricular cineangiograms before dilation.

The pulmonary valve was characterized using the following angiographic and echocardiographic observations: 1) the presence or absence of nodular and uneven thickening of the leaflets, 2) lack of systolic doming, 3) pulmonary annulus hypoplasia, 4) supra-annular narrowing, and 5) absence of poststenotic dilation (10-12). When all such observations were present, the valve was considered dysplastic (13). The presence and degree of pulmonary regurgitation were graded from the width of the regurgitant jet (assessed by color flow mapping) at its origin, relative to the width of the pulmonary valve annulus (from parasternal short-axis view) and arbitrarily graded as severe when the ratio was  $>50\%$ .

**Technique of balloon dilation.** The technique for balloon dilation has previously been described (14) but was modified slightly for the neonate. During a maintenance prostaglandin infusion (0.1  $\mu\text{g}/\text{kg}$  body weight per min) and under general anesthesia, the right femoral vein was percutaneously entered, and right heart catheterization was performed with a 5F balloon-tipped angiographic catheter (Arrow). Subsequently, a biplane right ventriculogram was obtained in the anteroposterior (with 20° cranial angulation) and lateral projections with a contrast dose of 1 to 2 ml/kg (Isovue, Squibb) at a rate of 8 ml/s. The pulmonary valve ring was measured from the lateral projection in early systole from the replay monitor using the catheter for magnification correction (Siemens Inc., HICOR). The angiographic catheter was then replaced with a 5F right coronary catheter (2.5 curve, Cook Inc.) and, with the aid of a curved-tipped guide wire (Terumo), maneuvered through the pulmonary valve and ductus arteriosus into the descending aorta, where it was replaced with a 0.035-in. (0.89-mm) Teflon-coated wire (Cook Inc.). This latter maneuver better allowed the wire-guided balloon to track across the right ventricular outflow and to cross the pulmonary valve annulus. A balloon 1.2 to 1.3 times the measured pulmonary annulus was used and inflated rapidly two or three times. The balloon catheter was then withdrawn and replaced with the coronary catheter for a pressure pullback and, finally, a right ventriculogram obtained with the angiographic catheter.

**Statistical analysis.** To adjust for changing patient size and age, the pulmonary and tricuspid diameters were expressed relative to their distribution within the normal range as a Z score, equal to the measured diameter minus the mean normal diameter and divided by the standard deviation of the mean normal diameter for body surface area (6). A valve annulus

**Table 2. Morphologic Features of Pulmonary Valve and Outflow Tract**

	Pre BV (angio)	Pre BV (echo)	Latest (echo)	p Value*
PV Z score	-2.8 ± 1.0	-3.0 ± 1.0	0 ± 1.0	< 0.0001
PV hypoplasia	83%	87%	4%	< 0.0001
Poststenotic dilation	93%	59%	28%	0.038
Leaflet immobility	21%	66%	0%	< 0.0001
Systolic leaflet doming	93%	50%	4%	< 0.0001
Supraannular narrowing	3%	31%	0%	< 0.0001
Thickened leaflets	93%	93%	4%	< 0.0001
RV hypoplasia	43%	35%	4%	0.034
TV Z score	0 ± 1.0	-0.1 ± 1.0	0 ± 1.0	NS

\*Echocardiographic (echo) variables before balloon dilation versus those from the latest echocardiogram. Data presented are mean value ± SD or percent of patients. angio = angiography; BV = balloon valvotomy; PV = pulmonary valve; RV = right ventricular; TV = tricuspid valve.

was considered hypoplastic when the calculated Z score was -2 or lower. Normally distributed continuous data are presented as mean values ± standard deviation and range. Prevalvotomy and postvalvotomy continuous variables were analyzed by two-tailed paired Student *t* test. An unpaired *t* test was used to compare continuous data between patients with and without a dysplastic valve or with and without a hypoplastic right ventricle. Nominal variables were analyzed using a Fisher exact test and chi-square test where appropriate. The Pearson correlation coefficient was used to compare angiographic and echocardiographic numerical data. A Cohen kappa analysis (15) was applied to compare the angiographic and echocardiographic determinations of right ventricular hypoplasia. A Kaplan-Meier analysis was used to evaluate the freedom from further reintervention (percutaneous balloon dilation or surgical procedure) after the initial balloon dilation. A value of *p* < 0.05 was taken as statistically significant.

## Results

**Initial hemodynamic and morphologic findings.** All patients had clinical and echocardiographic findings consistent

with critical right ventricular outflow tract obstruction at the pulmonary valve level. Pulmonary blood flow was ductus dependent in 15 neonates. Percutaneous room air oxygen saturation at presentation was 80 ± 7% (mean ± SD) (range 61 to 93%), and estimated transvalvular peak instantaneous Doppler gradient was 82 ± 19 mm Hg (range 41 to 120). The right atrium was dilated, the atrial septum bowing toward the left atrium, and the foramen ovale was patent in all patients at initial echocardiograms, with a pure right to left shunt in 23% and bidirectional (but predominantly right to left) flow in the remainder.

Echocardiographic pulmonary and tricuspid annulus diameter Z scores were -3.0 ± 1.0 and -0.1 ± 1.0, respectively, and correlated well with angiographic measurements (*r* = 0.78, *p* ≤ 0.001 and *r* = 0.75, *p* ≤ 0.001, respectively) (Table 2). Although most patients had some criteria for valve dysplasia at initial study, only nine (24%) fulfilled all criteria (Table 3).

Right ventricular hypoplasia determined by the angiographic index, angiographic tripartite approach and echocardiographic assessment was noted in 16 (43%), 16 (43%) and 14 (35%) neonates, respectively (Table 4), with a strong correlation between the two angiographic methods (kappa 0.87, *p* ≤

**Table 3. Comparison Between Effects of Balloon Valvotomy in Patients With and Without Valve Dysplasia**

	Nondysplastic (n = 28)	Dysplastic (n = 9)	p Value
Age (days)	12.0 ± 11.0	11.0 ± 9.0	NS
Weight (kg)	3.5 ± 1.0	3.4 ± 0.4	NS
Achieved balloon dilation	26/28 (93%)	9/9 (100%)	NS
Pre-BV Doppler ΔP (mm Hg)	83 ± 20	79 ± 18	NS
Pre-BV catheter ΔP (mm Hg)	60 ± 20	58 ± 28	NS
Post-BV catheter ΔP (mm Hg)	11 ± 11	10 ± 10	NS
Latest Doppler ΔP (mm Hg)	13 ± 7	19 ± 11	NS
Pre-BV RV/AO pressure ratio	1.3 ± 0.4	1 ± 0.4	NS
Post-BV RV/AO pressure ratio	0.6 ± 0.2	0.7 ± 0.2	NS
Fluoroscopy time (min)	21.0 ± 15.0	29 ± 23	NS
Procedure time (min)	81 ± 40	77 ± 25	NS
Mortality	2/28 (7%)	1/9 (11%)	NS
Reintervention	2/24 (8%)	2/8 (25%)	NS

Data presented are mean value ± SD or percent of patients. AO = aortic; ΔP = transvalvular systolic gradient; other abbreviations as in Table 2.

**Table 4.** Comparison Between Effects of Balloon Valvotomy in Patients With and Without Right Ventricular Hypoplasia

	Nonhypoplastic (n = 21)	Hypoplastic (n = 16)	p Value
Age (days)	13.0 ± 16.0	9.0 ± 9.0	NS
Weight (kg)	3.6 ± 0.6	3.5 ± 0.7	NS
Achieved balloon dilation	21/21 (100%)	14/16 (87.5%)	NS
Pre-BV Doppler ΔP (mm Hg)	81.0 ± 19.0	84 ± 20	NS
Pre-BV catheter ΔP (mm Hg)	62.0 ± 18.0	60 ± 23	NS
Post-BV catheter ΔP (mm Hg)	12.0 ± 12.0	8.0 ± 8.0	NS
Latest Doppler ΔP (mm Hg)	15.0 ± 8.0	14.0 ± 8.0	NS
Pre-BV RV/AO pressure ratio	1.3 ± 0.3	1.3 ± 0.5	NS
Post-BV RV/AO pressure ratio	0.6 ± 0.2	0.7 ± 0.2	NS
Fluoroscopy time (min)	23.0 ± 17.0	23 ± 19	NS
Mortality	0/21 (0%)	3/16 (18.7%)	NS
Reintervention	2/21 (9.5%)	2/16 (12.5%)	NS

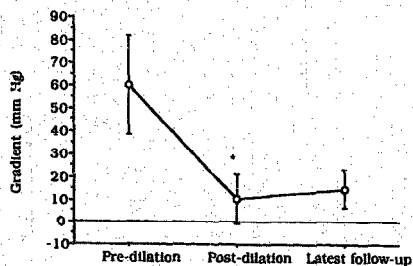
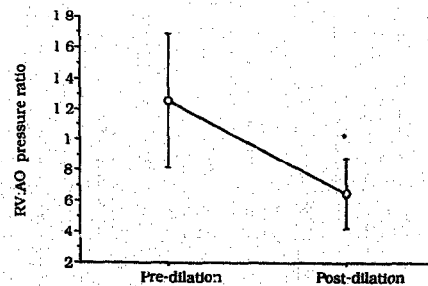
Data presented are mean value ± SD or percent of patients. Abbreviations as in Tables 2 and 3.

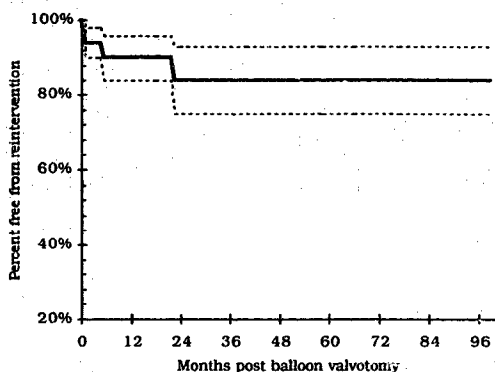
0.001) and between the echocardiographic and angiographic approaches ( $\kappa = 0.79$ ,  $p \leq 0.001$ ). Of the 16 patients with ventricular hypoplasia (as determined by the tripartite morphologic approach), all had attenuation of the trabecular portion of the ventricle.

**Immediate results.** Balloon dilation was attempted in 37 patients (95%), and in 2 of these, the right ventricular outflow tract could not be traversed, necessitating subsequent surgical valvotomy. One of these patients had a persistent valvular obstruction after operation and required balloon dilation 10 weeks later. The transvalvular systolic gradient (at catheterization) decreased from  $60 \pm 22$  mm Hg (range 20 to 100) to  $11 \pm 10$  mm Hg (range 0 to 45) ( $p < 0.0001$ ) (Fig. 1), and the right ventricular/aortic systolic pressure ratio decreased from  $1.25 \pm 0.43$  (range 0.5 to 2.6) to  $0.66 \pm 0.22$  (range 0.2 to 1) ( $p < 0.0001$ ) immediately after balloon dilation (Fig. 2). No statistically significant differences were found in the results of balloon dilation for patients with or without valve dysplasia (Table 3) nor for patients with or without right ventricular hypoplasia (Table 4). The balloon diameter/annulus ratio was  $1.2 \pm 0.1$  (range 1.0 to 1.5). Median procedure time and fluoroscopy time was 70 min (range 40 to 185) and 18 min (range 10 to 82), respectively. Median hospital stay after

balloon dilation was 4 days (range 1 to 26). There was no difference in immediate hemodynamic outcomes between those dependent or not dependent on ductal patency for additional pulmonary blood flow. Twenty-five percent of patients were discharged within 24 h, and 75% within 9 days. Patients were generally weaned from prostaglandin in 1 to 2 days. However, six patients required prolonged infusion periods (range 3 to 12 days) thought to be related to persistently impaired right ventricular compliance. Percutaneous oxygen saturation improved significantly ( $p < 0.0001$ ) after balloon dilation and was  $92 \pm 4\%$  (range 80% to 98%) at hospital discharge.

**Complications.** Of the 35 patients who underwent dilation, 3 died (8%). One death occurred 8 days after an initially successful balloon dilation. Postmortem examination demonstrated thrombosis of the inferior vena cava with infarction of the right kidney from thrombus extension into the right renal vein, presumably originating from femoral vein injury at the time of the catheterization. The second death occurred in a 1.9-kg neonate with a 4p- chromosomal deletion who, in addition to critical pulmonary valve stenosis and hypoplasia of the right ventricle, had ventriculocoronary artery connections

**Figure 1.** Comparison of transvalvular systolic gradients (mean value ± SD) before, immediately after and at latest follow-up. \* $p < 0.0001$  versus predilation gradient.**Figure 2.** Comparison of right ventricular/aortic pressure ratio (mean value ± SD) before and immediately after balloon valvotomy. \* $p < 0.0001$  versus predilation ratio.

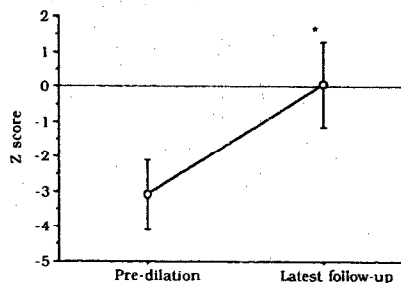


**Figure 3.** Freedom from reintervention (determined by Kaplan-Meier analysis) after balloon dilation for neonatal pulmonary stenosis (n = 35). Dashed line encloses the 70% confidence interval.

without stenosis or atresia. Despite an initially successful balloon dilation, the patient died 3 weeks after the procedure. The request for postmortem examination was declined. The third death occurred in a patient 1 day after surgical intervention (right ventricular outflow tract patch), which was performed 2 weeks after balloon valvotomy. Postmortem study showed extensive subendocardial replacement fibrosis with endocardial fibroelastosis and residual outflow tract obstruction. There were two additional major complications: one patient developed acute tamponade as a result of perforation of the right ventricular outflow tract from guide wire manipulation after a successful dilation and required surgical decompression, and a second patient with a preexisting cerebral infarction from a traumatic delivery developed nonsustained unifocal seizures after the procedure.

**Reinterventions.** During a median follow-up of 31 months, 2 (6%) of the remaining 32 patients required surgical intervention, a systemic to pulmonary shunt in 1 and right ventricular outflow tract patch in another (1 and 2 weeks after balloon dilation, respectively). The former developed stable hemodynamic function and a non-shunt-dependent circulation at 3 months of follow-up and underwent successful transcatheter occlusion of the shunt at 6 months of age. The latter died postoperatively (see complications). Two patients (6%) have had repeated balloon dilation at 5 and 23 months of age due to recurrence of valve gradients  $\geq 50$  mm Hg. Freedom from reintervention was 90%, 84% and 84% at 1, 2 and 8 years, respectively (Fig. 3), and the prevalence was not related to ductal dependency at presentation.

**Late hemodynamic and morphologic findings.** Estimated transvalvular peak instantaneous Doppler gradients at latest follow-up (median 31 months, range 6 months to 8 years) were  $15 \pm 9$  mm Hg (range 6 to 36) (Fig. 1). Pulmonary annulus Z score increased from  $-3.0 \pm 1.0$  to  $0 \pm 1.0$  ( $p < 0.0001$ ), with a normalization of the pulmonary annulus diameter observed (Fig. 4). The tricuspid valve annulus grew normally with a stable Z score during follow-up ( $-0.1 \pm 1.0$  vs.  $0 \pm 1.0$ ,  $p = ns$ ).



**Figure 4.** Changes in pulmonary annulus diameter Z score (mean value  $\pm$  SD) after balloon valvotomy. \* $p < 0.0001$  versus predilation score.

(Table 2). Thickening of valve leaflets, initially present in 93%, was found in only 4% at latest evaluation, and leaflet mobility improved in all. Hypoplasia of the right ventricle, initially present in 35%, was present in only 4% at follow-up (Table 2).

The atrial septum was convex toward the left atrium at presentation in all and positioned normally at follow-up. A patent foramen ovale, observed in all before the dilation (with either right to left or bidirectional shunting), was found during follow-up in only four patients, and only one had a left to right shunt. Color flow mapping suggested severe pulmonary regurgitation in only three patients (9.3%).

## Discussion

The immediate success of balloon dilation for critical pulmonary stenosis in neonates was reported in 1984 (16) and has been supported by several additional investigations (17-22). However, the long-term success of this procedure has not been established. The diversity of institutional management algorithms for critical pulmonary stenosis in the neonate and the limited patient numbers per institution have resulted in a lack of consistent follow-up data in this population (6). The present study analyzed medium-term results of balloon valvotomy performed in 37 consecutive neonates with critical pulmonary valve stenosis, addressing not only hemodynamic results but also morphologic consequences and clinical course.

**Immediate results.** Balloon valvotomy achieved successful relief of obstruction in the majority of cases, with only 6% requiring immediate surgical intervention and 6% needing repeat balloon dilation in follow-up. In our previous report of patients  $< 3$  months old (22), a significant problem was identified in crossing the stenotic valve and outflow tract, often associated with hypoplasia of the infundibulum. The present series reflects technical improvements in crossing the stenotic valve, largely from using a right coronary artery catheter. Additionally, a previous report (2) suggested the potential risk of rupture of the tricuspid valve using a non-Berman catheter; however, we did not encounter this complication in this series.

**Impact on pulmonary valves.** The majority of patients had evidence on initial echocardiographic or angiographic studies

of thickening of the pulmonary valve leaflets, hypoplasia of the pulmonary valve annulus or other criteria for valve dysplasia. This abnormal valve morphology was dramatically altered after balloon valvotomy, as seen in follow-up. Our data did not demonstrate a statistical difference in immediate or late results of balloon valvotomy for patients with or without dysplasia of the pulmonary valve (Table 3), which is similar to observations in older children (13) but differs from other reports that have regarded a dysplastic valve as a contraindication to balloon dilation (17,23,24). This finding although more subjective, suggests a morphologic maturation of the pulmonary valve and provides insight into the modified natural history of this group of patients.

**Right ventricular function and size.** There was a significant improvement in previously impaired right ventricular diastolic dysfunction, as evidenced by the evolution of normal right atrial size, normal alignment of the atrial septum (i.e., non-bowing) and lack of right to left shunting at the atrial level in all patients in follow-up.

A quantitative assessment of right ventricular size in follow-up would have been useful. However, because of the retrospective nature of the present study, and limitations to the echocardiographic determination of the right ventricular volumes (25,26), objective analysis was not possible; standardized images to estimate volumes were available in very few patients. An echocardiographic approach to ventricular morphology was therefore applied, and it correlated well with the angiographic assessment. Follow-up echocardiographic evaluations revealed less right ventricular hypoplasia (4%) than at time of diagnosis (43%). Such progression has been illustrated in some reports of right ventricular growth after pulmonary valvotomy (6,9), supporting the notion that in patients with critical pulmonary valve stenosis, areas of apparent hypoplasia may only reflect hypertrophied regions of the right ventricle so overgrown by myocardium as to be effectively absent and unable to contribute to the ventricular stroke volume. However, with reduction in afterload and relief of the obstruction, there is regression of the hypertrophy and normalization of cavity size (6,9).

**Conclusions.** These data support the application of balloon valvotomy as initial intervention in the algorithm for neonates with critical pulmonary valve stenosis. Medium-term follow-up observations demonstrate sustained hemodynamic relief and support maturation of the right ventricle and pulmonary valve annulus, with the expectation of a good long-term outcome.

## References

- Kan JS, White RI, Mitchell SE, Gardner TJ. Percutaneous balloon pulmonary valvuloplasty. A new method for treating congenital pulmonary valve stenosis. *N Engl J Med* 1982;307:540-2.
- Stanger P, Cassidy SC, Girod DA, Kan JS, Labadidi Z, Shapiro SR. Balloon pulmonary valvuloplasty: result of the Valvuloplasty and Angioplasty of Congenital Anomalies Registry. *Am J Cardiol* 1990;65:775-83.
- McCordle BW, Kan SJ. Long-term results after balloon pulmonary valvuloplasty. *Circulation* 1991;83:1915-22.
- Masura J, Durch M, Deanfield JE, Sullivan ID. Five year follow-up after balloon pulmonary valvuloplasty. *J Am Coll Cardiol* 1993;21:132-6.
- McCordle BW. Independent predictors of long-term results after balloon pulmonary valvuloplasty. Valvuloplasty and Angioplasty of Congenital Anomalies Registry Investigators. *Circulation* 1994;89:1751-9.
- Hanley FL, Sade RM, Freedom RM, Blackstone E, Kirklind JW. Outcomes in critically ill neonates with pulmonary stenosis and intact ventricular septum: a multi-institutional study. *J Am Coll Cardiol* 1993;22:183-92.
- Lewis AB, Wells W, Lindesmith GG. Evaluation and surgical treatment of pulmonary atresia and intact ventricular septum in infancy. *Circulation* 1983;67:1318-23.
- Goor DA, Lillehei CW. *Congenital Malformations of the Heart*. New York: Grune & Stratton, 1975:11.
- Bull C, De Leval M, Mercanti C, Macartney FJ, Anderson RH. Pulmonary atresia and intact ventricular septum: a revised classification. *Circulation* 1982;66:266-72.
- Jeffery RF, Moller JH, Amplatz K. The dysplastic pulmonary valve: a new roentgenographic entity. *Am J Roentgenol Rad Ther Nucl Med* 1972;114:322-39.
- Koretzky ED, Moller JH, Korn ME, Schwartz CJ, Edwards JE. Congenital pulmonary stenosis resulting from dysplasia of the valve. *Circulation* 1969;40:43-53.
- Musewe N, Robertson MA, Benson LN, et al. The dysplastic pulmonary valve: echocardiographic features and results of balloon dilation. *Br Heart J* 1987;57:364-70.
- Rao PS. Balloon pulmonary valvuloplasty: a review. *Clin Cardiol* 1989;12:55-74.
- Robertson M, Benson LN, Smolhorn JS, et al. The morphology of the right ventricular outflow tract after percutaneous pulmonary valvotomy: long-term follow-up. *Br Heart J* 1987;58:239-44.
- Norman GR, Streiner DL. *Biostatistics. The Bare Essentials*. St. Louis: Mosby-Year Book, 1994:164.
- Tynan M, Jones O, Joseph MC, Deverall PB, Yates AK. Relief of pulmonary valve stenosis in the first week of life by percutaneous balloon valvuloplasty [letter]. *Lancet* 1984;1:273.
- Sullivan ID, Robinson PJ, Macartney FJ, et al. Percutaneous balloon valvuloplasty for pulmonary valve stenosis in infants and children. *Br Heart J* 1985;54:435-41.
- Rey C, Marache P, Francart C, Dupuis C. Percutaneous transluminal balloon valvuloplasty for congenital pulmonary valve stenosis, with special report on infants and neonates. *J Am Coll Cardiol* 1988;11:815-20.
- Zeevi B, Keane JF, Fellows KE, Lock JE. Balloon dilation of critical pulmonary stenosis in the first week of life. *J Am Coll Cardiol* 1988;11:821-4.
- Guarnera S, Piechard JF, Kachaner J, et al. Traitement des sténoses valvulaires pulmonaires critiques du nouveau-né par valvuloplastie percutanée: étude de 28 cas. *Arch Fr Pédiatr* 1989;46:503-8.
- Ladusans EJ, Qureshi SA, Parsons JM, Arab S, Baker EJ, Tynan M. Balloon dilation of critical stenosis of the pulmonary valve in neonates. *Br Heart J* 1990;63:362-7.
- Caspi J, Coles JG, Benson LN, et al. Management of neonatal critical pulmonary stenosis in the balloon valvotomy era. *Ann Thorac Surg* 1990;49:273-8.
- Tynan M, Baker EJ, Rohmer J, et al. Percutaneous balloon pulmonary valvuloplasty. *Br Heart J* 1985;53:520-4.
- Kan JS, White RI, Mitchell SE, Anderson JH, Gardner TJ. Percutaneous transluminal balloon valvuloplasty for pulmonary valve stenosis. *Circulation* 1984;69:554-60.
- Snider AR, Serwer GA. Methods for obtaining quantitative information from the echocardiographic examination. In: Snider AR, Serwer GA, editors. *Echocardiography in Pediatric Heart Disease*. St. Louis: Mosby-Year Book, 1990:78-133.
- Freedom RM. How can something so small cause so much grief? Some thought about the underdeveloped right ventricle in pulmonary atresia and intact ventricular septum [editorial comment]. *J Am Coll Cardiol* 1992;19:1038-40.