

Infrapopliteal Transcatheter Interventions for Limb Salvage in Diabetic Patients: Importance of Aggressive Interventional Approach and Role of Transcutaneous Oximetry

GEORGE P. HANNA, MD,* KEN FUJISE, MD,* OLLE KJELLGREN, MD,* STEVEN FELD, MD,* CAROLINE FIFE, MD,*† GEORGE SCHROTH, MD,* TOM CLANTON, MD,* VERNON ANDERSON, MD,* RICHARD W. SMALLING, MD, PhD, FACC*

Houston, Texas

Objectives. This study sought to determine whether infrapopliteal transcatheter interventions can salvage ischemic limbs in diabetic patients referred for below the knee amputation at our institution.

Background. The value of transcatheter interventions in diabetic crural arteries is controversial. Tissue oxygen partial pressure (Tco₂) levels <40 mm Hg predict poor wound healing.

Methods. Percutaneous interventions were performed in 29 consecutive diabetic patients in need of limb salvage. **Technical success** was defined as <20% residual vessel stenosis. **Clinical success** was defined as the avoidance of amputation and achievement of wound healing. At hospital discharge, patients were treated with Coumadin and aspirin. Ankle-brachial index (ABI) and Tco₂ measurements were obtained before and after the intervention.

Results. After 12-month follow-up, six patients had persistent wounds, whereas 23 experienced wound healing. Forty of the 50 infrapopliteal arteries successfully dilated were occluded, with a mean (±SD) lesion length of 18.0 ± 3.5 cm. After the procedure, Tco₂ improved from 27.82 ± 9.97 mm Hg (95% confidence interval [CI] 23.95 to 31.69) to 54.5 ± 14.73 mm Hg (95% CI 48.79 to 60.21, p < 0.0001), whereas the ABI did not (p > 0.2). Tco₂ predicted procedural and clinical success (p < 0.0182).

Conclusions. Infrapopliteal transcatheter interventions in diabetic patients may salvage the majority of limbs doomed to amputation. Although Tco₂ measurements are valuable in predicting wound healing and success after interventions, ABI measurements are not.

(J Am Coll Cardiol 1997;30:664-9)
©1997 by the American College of Cardiology

Peripheral vascular disease (PVD) in diabetic patients constitutes a major clinical problem and is associated with high morbidity and mortality. Diabetic patients are five times more likely to develop critical limb ischemia than nondiabetic patients (1). Moreover, Beach et al. (2) observed that 42% to 48% of men and 28% to 35% of women with type II diabetes develop PVD. One serious complication of PVD in humans is gangrene, which accounts for ~50% of lower limb amputations in diabetic patients in the Western world (1). In the United States, it is estimated that 280 lower limb amputations/million population are performed annually (3), with a cost to society estimated in the hundreds of millions of dollars and a devastating psychological impact on patients. In addition, one series (4,5) showed that postoperative complications, including revisions, reamputation at a higher level and mortality, may occur

in 34% of patients, with the mortality rate ranging from 6% to 13%, depending on the amputation procedure (4,5).

Percutaneous transluminal coronary angioplasty (PTCA) and stenting are well documented as beneficial techniques in the treatment of iliac and femoropopliteal PVD (6,7). However, experience in applying these techniques to infrapopliteal vessels is limited. Moreover, the disappointing results of infrapopliteal bypass surgery (8,9) prompted interventionalists over the years to refrain from using infrageniculate procedures, except in select cases of limb salvage (10,11). Dorros et al. (12) reported a success rate of 65% for occluded tibioperoneal vessels.

Noninvasive vascular tests are important in the evaluation and management of patients with PVD. Ankle-brachial index (ABI) measurement is a noninvasive, cost-effective and frequently used method. However, in diabetic patients ABI may not be as reliable, because these patients tend to have calcified arteries (13). In addition, the pressures in large vessels do not necessarily reflect the adequacy of blood flow to ischemic tissue. Finally, ankle surgery and ischemic wounds may interfere with measurement taking. Transcutaneous oxygen pressure (Tco₂) measurement, in contrast, is a noninvasive method of measuring oxygen tension at the skin surface produced by heat-induced hyperemia. This method is used for a variety of

From the *Division of Cardiology, Department of Medicine and Departments of Anesthesiology and Orthopedic Surgery, University of Texas Medical School and †Hyperbaric Oxygen Center, Hermann Hospital, Houston, Texas.

Manuscript received September 13, 1996; revised manuscript received May 21, 1997, accepted May 30, 1997.

Address for correspondence: Dr. Richard W. Smalling, Division of Cardiology, Department of Medicine, University of Texas Medical School, MSB 1.246, 6431 Fannin Street, Houston, Texas 77030. E-mail: smalling@heart.med.uh.tmc.edu.

Abbreviations and Acronyms

- ABI = ankle-brachial index
- BKA = below the knee amputation
- CI = confidence interval
- HBO = hyperbaric oxygen
- PTCA = percutaneous transluminal coronary angioplasty
- PVD = peripheral vascular disease
- SFA = superficial femoral artery
- Tco₂ = tissue oxygen partial pressure

conditions, including PVD evaluation (14-18), predicting the outcome of patients requiring amputation (19) and survival of skin grafts (20). However, Tco₂ is affected by many variables, including oxygen concentration in inspired air, lung function, hemoglobin saturation, cardiac output, as well as local factors, such as skin thickness, presence of inflammation and infection, edema, capillary formation and skin oxygen consumption.

This study sought to determine whether aggressive infra-popliteal interventions for limb salvage in diabetic patients could prevent leg amputation and allow wound healing and whether Tco₂ was superior to ABI measurement in predicting procedural and clinical success.

Methods

Patient selection and technique. Between December 1993 and February 1996, 29 consecutive diabetic patients with nonhealing foot ulcers underwent femoral angiography with distal runoff and were treated initially with vascular surgery. All patients had at least two infrageniculate arterial stenoses or occlusions and were deemed candidates for below the knee amputation (BKA) and not surgical revascularization because of poor distal targets. These patients were then referred for possible transcatheter interventions for limb salvage. Table 1 summarizes the characteristics of the patients. All procedures were performed by one of three experienced interventional cardiologists (R.W.S., G.S., V.A.) using a small vessel dilation catheter system (Baxter, Medi-Tech, SCIMED or USCI). The procedure typically used antegrade puncture of the ipsilateral common femoral artery with insertion of a short 6F

sheath. In cases where the proximal portion of the ipsilateral femoral artery needed PTCA, a retrograde contralateral common femoral artery puncture was performed with insertion of a long 6F or 7F sheath over the aortic bifurcation. A series of angiograms were then obtained. On-line quantitative angiography (Phillips DCI) was used to measure vessel diameters and to determine balloon size. Obstructive above the knee lesions, if present, were treated with balloon angioplasties, except for two patients in whom rotational atherectomy was performed (Bard Xtractor). After adequate results were confirmed by repeat angiography, infrageniculate lesions were approached. An 80-cm, 6F multipurpose guiding catheter was advanced to the popliteal artery. The lesions were crossed either with a 0.014-in. (0.035 cm) standard coronary wire or with a 0.035-in. (0.089 cm) Terumo wire. A low profile balloon dilation catheter was advanced over the wire to the most distal region possible. Several inflations were performed over the entire length of the lesion. Repeat inflations were performed with larger size balloons if indicated. When more than one artery was occluded, an attempt was made to open as many arteries as possible. The length of the lesion was not a deterrent to performing the procedure. All patients received aspirin (325 mg orally) at least 1 day before the procedure and heparin (7,000 U intraarterially) once the sheath was in place. Repeat heparin boluses were administered to maintain an activated clotting time >250. Intraarterial boluses of nitroglycerin (200 to 500 µg) were administered as necessary when spasm occurred. Also, urokinase (500,000-U bolus) and then a 24- to 48-h infusion (1,200 U/min) were administered intraarterially at the discretion of the interventionalist for treating thrombi after the procedure. Patients in whom the technique was successful received intravenous heparin to keep the partial thromboplastin time 1.5 times the control value for 24 to 48 h after the intervention. All patients were closely monitored during the procedure and for an average of 24 to 72 h after the procedure in an intensive care setting. On hospital discharge, all patients with successful interventions received anticoagulant therapy with Coumadin (international normalized ratio 2.0 to 2.5) for 6 weeks and aspirin (325 mg/dy) indefinitely.

Tco₂ and ABI measurements. Noninvasive measurements of Tco₂ and ABI were obtained for all patients. Transcutaneous oximetry was obtained using the Radiometer/Copenhagen TCM2 machine. A Clark-type electrode was calibrated and applied to the skin, after which the skin was warmed to 44°C before obtaining readings. The skin area had previously been vigorously rubbed and cleansed with alcohol swabs. The electrode was applied to clinically viable tissue in the vicinity of and proximal to the foot ulcer, with the patient supine and breathing room air, and allowed to equilibrate for 15 to 20 min. This procedure was performed before and within 2 weeks of the transcutaneous intervention. The last Tco₂ measurement documented in the patient's record was chosen to represent his or her pre-PTCA Tco₂ value. A Polaroid photograph of the extremity with electrodes in place taken before the intervention was used to aid the technician measuring Tco₂ to use the same skin testing area when obtaining postintervention Tco₂.

Table 1. Demographic Data for 29 Patients

Age (yr)	62 ± 2.5
Men/women	12/17
Coronary artery disease	21 (72%)
Previous fem/pop	3 (10%)
Hypertension	23 (79%)
Smoking	16 (55%)
Previous amputations	2 (7%)
Renal failure*	7 (24%)
S/P renal transplant	1 (3%)

*Patients receiving peritoneal dialysis or hemodialysis. Data presented are mean value ± SD or number (%) of patients. fem/pop = femoral/popliteal arterial revascularization; S/P = status post.

Table 2. Results of Percutaneous Transluminal Coronary Angioplasty in 29 Patients

Infrapopliteal vessels dilated/attempted	
Peroneal	13/17 (77%)
Anterior tibial	25/28 (89%)
Posterior tibial	11/12 (91%)
Dorsalis pedis	1/1 (100%)
Total	50/58 (86%)
Concurrent vessels dilated/attempted	
SFA	13/16 (81%)
Popliteal	12/14 (86%)
Total	25/30 (83%)
Complications	
Infrapopliteal thrombi	2
Other thrombi	4
Total	6

Data presented are number (%) of patients. SFA = superficial femoral artery.

ABI measurements were also obtained before and within 2 weeks of the intervention on follow-up in the outpatient cardiovascular center. Patients continued to receive hyperbaric oxygen (HBO) treatments after the intervention, as deemed appropriate by the supervising physician in the HBO Center.

Statistical methods. Results are presented as mean value \pm SD. Statistical analysis was performed using two-factor analysis of variance. A probability value of 0.05 was considered significant.

Results

Technical and clinical results. Twenty-nine diabetic patients with severe infrapopliteal arterial stenosis underwent PTCA in an attempt to salvage limbs doomed to amputation. Table 2 summarizes the PTCA results. *Technical success* was defined as $<20\%$ residual stenosis using quantitative angiography of any of the infrageniculate vessels dilated with flow reestablished at the ankle level, as determined by runoff angiography. *Clinical success* is defined by healing of the ulcer and avoidance of leg amputation. We did not consider amputation of previously gangrenous toes a failure. Forty of the 50 infrapopliteal vessels successfully dilated were occluded, with a mean (\pm SD) lesion length of 18.0 ± 3.5 cm. After a mean follow-up period of 12 months, 23 patients (79%) experienced progressive wound healing, with 15 (65%) being discharged from the HBO Center by the end of follow-up. Mean time to wound healing was 3 months. However, six patients (21%) did not fare well: Patients 1 and 2 had BKA due to osteomyelitis. Both of these patients had technically successful interventions. Patient 29 had a successful intervention but a progressively worsening ulcer. Procedures for Patients 15, 23 and 25 were aborted because of unsuccessful attempts to negotiate lesions characterized by heavily calcified occluded vessels, and all three patients had BKAs. Twenty-one patients had concurrent noninfrageniculate vessels dilated. Patient 22 had superficial femoral artery (SFA) and proximal posterior tibial artery

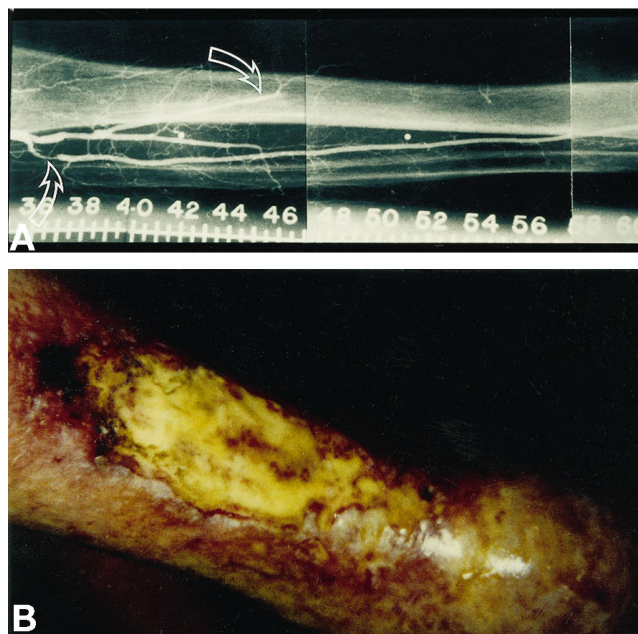


Figure 1. Preangioplasty angiogram showing (A) occluded peroneal and posterior tibial arteries (bottom arrow) and stenosed anterior tibial artery (top arrow) and (B) severe, nonhealing lower extremity ulcer in the same patient.

disease with critical stenosis of a prominent perigenicular collateral vessel extending from the distal SFA to the mid posterior tibial artery. The stenotic lesion also extended below the level of the tibioperoneal trunk and was successfully dilated with good flow. Figures 1 and 2 show a successful intervention in one study patient. Procedures in four patients were complicated by thrombus formation in either the popliteal artery or SFAs and in two patients by infrapopliteal thrombi. Thrombolysis was successful in all patients who also received urokinase (Abbokinase, Abbott) in a 500,000-U intraarterial bolus and 24- to 48-h infusion (1,200 U/min) without major bleeding complications. Patient 7 received urokinase because of sluggish distal flow, but the presence of thrombus was not confirmed by angiography. Patient 13 died of ischemic heart disease 2 months after a successful procedure. He had improved T_{CO_2} and a progressively granulating ulcer at the time of his death.

T_{CO_2} and ABI results. Transcutaneous oximetry was measured in all patients before and within 2 weeks of the procedure. Tables 3 and 4 summarize the T_{CO_2} and ABI results. T_{CO_2} improved in all but two patients with successful interventions, as well as in all patients who eventually had healed or healing ulcers. T_{CO_2} improved from 27.8 ± 9.97 mm Hg (95% confidence interval [CI] 23.95 to 31.69) to 54.5 ± 14.73 mm Hg (95% CI 48.79 to 60.21, $p < 0.0001$). In fact, postintervention T_{CO_2} was predictive of both procedural and clinical success ($p < 0.0182$). However, Patients 1 and 29 continued to have low T_{CO_2} values despite technically successful interventions. Although follow-up angiography was not available, this persistently low T_{CO_2} value may have been due to the presence of

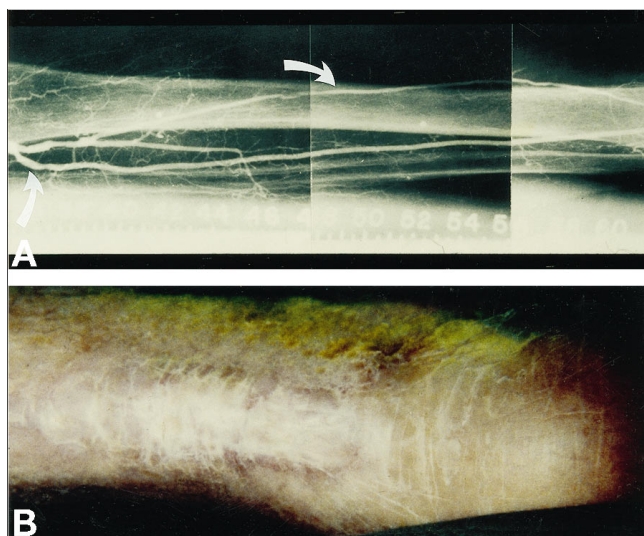


Figure 2. Postangioplasty angiogram showing (A) patent posterior tibial artery (bottom arrow) to below the ankle level and dilated anterior tibial artery (top arrow), and (B) healed ulcer after 8 months of follow-up.

severe microvascular disease, persistent infection or restenosis of the angioplasty site. The ABI was also obtained before and within 2 weeks of the intervention. The ABI values of three patients were not complete. Nonetheless, ABI measurements before and after the transcatheter intervention were not significant for either technically or clinically successful procedures ($p > 0.2$ and 0.4 , respectively).

Discussion

Study outcome. The present study demonstrates that infrapopliteal PTCA in diabetic patients with threatened limb loss is not only feasible but is also associated with a high rate of success and a low incidence of complications. Twenty-three patients (79%) were successfully treated, and during 12 months of follow-up their foot ulcers underwent progressive healing, and BKA was avoided. Only six patients (21%) did not fare well; three of them continued to have nonhealing ulcers despite a successful technical intervention. Two of the three required a BKA, and the third had a nonhealing ulcer. From a technical standpoint, 26 patients (90%) had successful PTCA. The remaining three patients had severe SFA and popliteal disease, with unsuccessful attempts to cross the lesions by an antegrade approach (a popliteal approach was used in one of them, also unsuccessfully), and all three patients' limbs were

Table 3. Results of Transcutaneous Oximetry

	Before Tco ₂ (mm Hg)	After Tco ₂ (mm Hg)	p Value
Technical success (n = 26)	29.27 ± 9.57	57.58 ± 10.02	< 0.0001
Clinical success (n = 23)	27.82 ± 9.97	54.5 ± 14.73	< 0.0001

Data presented are mean value ± SD. Tco₂ = tissue oxygen partial pressure.

Table 4. Results of Ankle-Brachial Index Measurement

	Before ABI Measurement	After ABI Measurement	p Value
Technical success (n = 26)	0.68 ± 0.17	0.67 ± 0.19	> 0.2
Clinical success (n = 23)	0.70 ± 0.17	0.70 ± 0.19	> 0.4

Data presented are mean value ± SD. ABI = ankle-brachial index.

amputated. This interventional success rate for occluded infrapopliteal vessels is better than that previously reported and may be due to refinements in guide wire and balloon technology that allowed infrapopliteal angioplasty without the vessel trauma previously observed with the long, tapered tips of the earlier catheters. It is also conceivable that infrageniculate atherosclerotic lesions were not pursued vigorously enough for fear of vessel rupture leading to compartment syndrome (12). In addition, the generous use of intraarterial nitroglycerin throughout the procedure may have contributed to procedural success. There are no data to our knowledge addressing PTCA primarily for occluded infrapopliteal arteries in diabetic patients in need of limb salvage. However, two studies that primarily include claudicant patients have included a large number of diabetic patients with ischemic ulcers and gangrene. Schwarten and Cutliff (10) reported results of PTCA of 145 infrapopliteal vessels in 98 patients with class 2 or 3 chronic ischemia (59 patients were diabetic). The technical success rate was defined as residual stenosis <30%, and their overall primary anatomic success rate was 97%. In that study (10), those patients requiring major amputations were diabetic. Even more recently, Matsi et al. (20) reported results of PTCA for the treatment of chronic critical ischemia in 103 prospective patients, 79 of whom were diabetic. Gangrene was present in 32% of patients. The total number of infrapopliteal arteries dilated was 84, with a mean follow-up period of 12 months. Dilations and recanalizations were considered technically successful if the residual stenosis was <50% at control angiography after angioplasty. The mean total length of treated segments was 10.6 cm. The technical success rate for infrapopliteal procedures was 83%, and the cumulative limb salvage rates, as determined by Kaplan-Meier survival analysis when hemodynamic failures were excluded, were 62%, 54% and 54% at 1, 2 and 3 years, respectively. Taking into account that both study groups were not matched, the findings of Matsi et al. (20) approach those of the current study. However, the limb salvage rate of 62% at 1 year reported by Matsi et al. is lower than the 79% rate reported here; we attribute the difference to the use of HBO, aggressive local wound care and possibly to the routine use of aspirin and Coumadin after the procedure.

Technique and complications. In our series, 40 successfully dilated infrapopliteal vessels were occluded, with an average (± SD) length of 18.0 ± 3.5 cm. We used a highly steerable, 0.014-in (0.035 cm) coronary wire (USCI Standard) to cross the total obstruction in the majority of cases. The size of the balloon was determined on the basis of an on-line quantitative angiography system. The selection of the balloons based on

quantitative angiography allowed us to optimally dilate the lesion without causing rupture or major dissection of the vessels. In the past, only short lesions were approached with angioplasty. In the series of Schwarten and Cutliff (10), the mean length of dilated lesions was 3 cm (range 1 to 3). Lesions >5 cm were referred for surgical revascularization. Peripheral PTCA was rarely used for treating lesions >5 cm for fear of potential complications, such as vessel rupture, severe dissections and a high restenosis rate, and because of the seemingly superior results of infrapopliteal bypass surgery. However, our results demonstrate that longer lesions can be dilated successfully without the previously feared complications, a finding consistent with that of Matsi et al. (20). We did not observe any major dissections, vessel rupture or compartment syndromes. Arterial spasm was observed frequently but was managed successfully with generous intraarterial administration of nitroglycerin. Only four patients developed thrombi of either the popliteal artery or SFAs, and two patients developed infrapopliteal thrombi. All thrombi were managed successfully with intraarterial urokinase without major bleeding complications.

Potential contributing factors. In a follow-up period ranging from 1 to 30 months (mean 12 months), 23 (88%) of 26 patients in whom the technique was successful avoided BKAs and experienced progressive wound healing. Several factors may have culminated in this high clinical success rate. The role of HBO therapy as an adjuvant to revascularization procedures in the treatment of diabetic foot (21), as well as various types of wounds (22-26), is important. Continued HBO treatments after PTCA may have hastened wound healing, so that 15 (65%) of 23 patients were discharged from the HBO Center by the end of follow-up. In addition, all patients with technical success received anticoagulation with heparin followed by Coumadin and aspirin. This method of anticoagulation may have reduced early thrombotic reocclusions. The T_{CO_2} values improved to levels beyond tissue viability, from a mean of 27.82 to 54.5 mm Hg ($p < 0.0001$) in 26 (90%) of 29 patients with technical success. In fact, this improvement in T_{CO_2} provides direct evidence of improved tissue perfusion and indirect evidence of improved arterial flow. T_{CO_2} levels <40 mm Hg are not consistent with wound healing (27). This finding demonstrates that T_{CO_2} is a reliable method for assessing tissue viability because all T_{CO_2} values >40 mm Hg after the intervention had healing ulcers. In addition, T_{CO_2} predicted interventional success; levels improved in all but two patients with technical success. These two patients may have experienced vascular reocclusion, had severe microvascular disease or developed persistent infection. Local skin infection drives down T_{CO_2} levels in the setting of borderline perfusion. Because repeat angiography was not performed as part of this study, it is not known how many patients, if any, experienced arterial restenosis. Although a number of dilated infrapopliteal vessels may restenose, these vessels may remain patent long enough to allow development of collateral circulation to ischemic wounds, thus promoting healing. Finally, ABI measurements in our diabetic patients did not improve significantly after angioplasty, which confirms previous reports that diabetic

patients may have calcified arteries, providing unreliable ABI measurements (28).

Macro versus micro theory of pathogenesis. Over the years, the development of diabetic gangrene was believed to be due to a combination of PVD and peripheral neuropathy, with more emphasis on neuropathic pathophysiology and abnormal microcirculation (29). This emphasis has led to an increased incidence of lower extremity amputations in diabetic patients because revascularization procedures were thought to be suboptimal in reversing presumed small-vessel disease of diabetic ischemic limbs. However, there has recently been a new trend emphasizing large-vessel disease as the main culprit in the development of diabetic gangrene, with some investigators rejecting the concept of "microvascular disease" completely (30-33). Our findings are consistent with proponents of the "macrovascular disease" theory.

Moreover, recent reports (12,34) indicate that infrapopliteal PTCA in patients in Fontaine stage 2 and 3 can be performed with high technical success and low complication rates. Although long-term efficacy of infrapopliteal PTCA in all stages of disease needs to be assessed further, it appears, at least in the short term, to approach the success rate of bypass surgery and may have the potential added benefit of shorter hospital stay and lower cost.

Conclusions. PTCA performed in diabetic patients with ischemic limbs referred for amputation can be performed with a high technical success rate, obviating the need for amputations in most patients, and a low complication rate and can lead to wound healing when HBO is used as adjunctive therapy. Moreover, our findings are in agreement with the "macrovascular disease" theory stressing the importance of large-vessel disease in the pathophysiology of diabetic lower extremity gangrene. We also showed that T_{CO_2} is a more reliable method for predicting tissue viability and technical success of infrapopliteal interventions in this patient group than the simple Doppler-derived ABI, which was unreliable. The present findings suggest that patients with diseased crural arteries and a low T_{CO_2} would benefit from PTCA in conjunction with HBO treatments and local wound care before resorting to the much dreaded BKA. However, if T_{CO_2} levels remain below healing levels, lower extremity amputation may unfortunately be the only route left when surgical revascularization is ruled out as an option.

References

1. West KW. Epidemiology of diabetes and its vascular complications: report to U.S. National Commission on Diabetes. Scope and Impact of Diabetes 1975;3:56-60.
2. Beach KW, Brunzell JD, Conquest LL, Strandness DE. The correlation of arteriosclerosis obliterans with lipoproteins in insulin-dependent and non-insulin-dependent diabetes. Diabetes 1979;28:836-40.
3. Kacy SS, Wolma FJ, Flye MW. Factors affecting the results of below knee amputation in patients with and without diabetes. Surg Gynecol Obstet 1982;155:513-8.
4. Netz P, Stark A, Ringertz H. Amputations for vascular insufficiency. Prosthet Orthot Int 1983;7:9-14.

5. Borssen B, Lithner F. Amputations in diabetics and nondiabetics in Umea county 1971-1977. *Acta Med Scand Suppl* 1985;687:95-100.
6. van Andel GJ, van Erp WFM, Krepel VM, Breslau PJ. Percutaneous transluminal dilatation of the iliac artery: long term results. *Radiology* 1985;156:321-3.
7. Hewes RC, White RI, Murray RR. Long term results of superficial femoral artery angioplasty. *Am J Roentgenol* 1986;146:1025-9.
8. Sidawy AN, Menzoian JO, Cantelmo NL, LoGerfo FW. Effects of inflow and outflow sites on the results of tibioperoneal vein grafts. *Am J Surg* 1986;152:211-4.
9. Robison JG, Brewster DC, Abbott WM, Darling RC. Femoropopliteal and tibioperoneal artery reconstruction using human umbilical vein. *Arch Surg* 1983;118:1039-42.
10. Schwarten DE, Cutliff WB. Arterial occlusive disease below the knee: treatment with percutaneous transluminal angioplasty performed with low profile catheters and steerable guide wires. *Radiology* 1988;169:75-8.
11. Brown KT, Schoenberg NY, Moore ED, Saddekini S. Percutaneous transluminal angioplasty of infrapopliteal vessels: preliminary results and technical considerations. *Radiology* 1988;169:75-8.
12. Dorros G, Lewin RF, Jamnadas P, Mathiak ML. Below the knee angioplasty: tibioperoneal vessels, the acute outcome. *Cathet Cardiovasc Diagn* 1990;19:170-8.
13. Raines JK, Darling RC, Buth J. Vascular laboratory criteria for the management of peripheral vascular disease of the lower extremities. *Surgery* 1976;79:21-9.
14. Modesti PA, Boddi M, Poggesi L, Gensini GF, Neri Serneri. *J Vasc Dis* 1987;52:457-62.
15. Devehat LE, Khodabandehlou T. Transcutaneous oxygen pressure and hemorheology in diabetes mellitus. *Int Angiol* 1990;9:259-62.
16. Matsen FA, Wyss CR, Pedegana CR. Transcutaneous oxygen tension measurement in peripheral vascular disease. *Surg Gynecol Obstet* 1980;150:525-8.
17. Shoemaker WC, Vidyasagar D. Physiological and clinical significance of PtcO₂ measurements. *Crit Care Med* 1981;9:689-90.
18. Franzeck UK, Talke P, Bernestein EF, et al. Transcutaneous PO₂ measurements in health and peripheral occlusive disease. *Surgery* 1982;91:156-63.
19. Burgess EM, Masten FA, Wyss CR, Simmons CW. Segmental transcutaneous measurements of PO₂ in patients requiring below-the-knee amputation for peripheral vascular insufficiency. *J Bone Joint Surg* 1982;64:378-82.
20. Matsi PJ, Manninen HI, Suhonen MT, Pirinen AE, Soimakallio S. Chronic critical lower-limb ischemia: prospective trial of angioplasty with 1-36 months follow up. *Radiology* 1993;188:381-7.
21. Achaver BM, Kirby SB, Litke DK. Transcutaneous PO₂ in flaps: a new method of survival prediction. *Plast Reconstr Surg* 1980;65:738-41.
22. Davis JC. The use of adjuvant hyperbaric oxygen in treatment of diabetic foot. *Clin Podiatr Med Surg* 1987;4:429-37.
23. Riseman JA, Zamboni WA, Curtis A, Graham DR, Konard HR, Ross DS. Hyperbaric oxygen therapy for necrotizing fasciitis reduces mortality and the need for debridements. *Surgery* 1990;108:847-50.
24. Wattel F, Mathieu D, Coget JM, Billard V. Hyperbaric oxygen therapy in chronic vascular wound management. *Angiology* 1990;5:59-65.
25. Unger HD, Lucca M. The role of hyperbaric oxygen therapy in the treatment of diabetic foot ulcers and refractory osteomyelitis. *Clin Podiatr Med Surg* 1990;7:483-92.
26. Mathieu D, Wattel F, Bouachour G, Billard V, Defoin JF. Post-traumatic limb ischemia: prediction of final outcome by transcutaneous oxygen measurements in hyperbaric oxygen. *J Trauma* 1990;30:307-14.
27. Mani R, White JE. Methodology for investigating cutaneous perfusion. *Int J Microcirc Clin Exp* 1984;5:401-5.
28. Wyss CR, Robertson C, Love SJ. Relationship between transcutaneous oxygen tension, ankle blood pressure, and clinical outcome of vascular surgery in diabetic and nondiabetic patients. *Surgery* 1987;101:56-62.
29. Boulton AJM, Scarpello JHB, Ward JD. Venous oxygenation in the diabetic neuropathic foot: evidence of arteriovenous shunting? *Diabetologia* 1982;22:6-8.
30. Rosenblum BI, Pomposelli FB, Giurini JM, et al. Maximizing foot salvage by a combined approach to foot ischemia and neuropathic ulceration in patients with diabetes. *Diabetes Care* 1994;17:983-7.
31. LoGerfo FW, Gibbons GW, Pomposelli FB, Cambell DR, Miller A. Trends in the care of the diabetic foot: expanded role of arterial reconstruction. *Arch Surg* 1992;127:617-21.
32. Pomposelli FB, Jepsen SJ, Gibbons GW. Efficacy of dorsalis pedis bypass for limb salvage in diabetic patients. *J Vasc Surg* 1990;11:745-52.
33. Pomposelli FB, Jepsen SJ, Gibbons GW, et al. A flexible approach to infrapopliteal vein grafts with diabetes mellitus. *Arch Surg* 1991;162:724-9.
34. Sivananthan UM, Browne TF, Thorley PJ, Rees MR. Percutaneous transluminal angioplasty of the tibial arteries. *Br J Surg* 1994;81:1282-5.