

Coronary Endothelial Dysfunction After Kawasaki Disease: Evaluation by Intracoronary Injection of Acetylcholine

RUMI YAMAKAWA, MD, MASAHIRO ISHII, MD, TETSU SUGIMURA, MD, TEIJI AKAGI, MD, GENZYU ETO, MD, MOTOHUMI IEMURA, MD, TAKAHIRO TSUTSUMI, MD, HIROHISA KATO, MD, FACC

Kurume, Japan

Objectives. This study sought to assess the endothelial function of long-term coronary artery lesions in patients with Kawasaki disease (KD).

Background. The vascular function of the coronary arteries in children with long-term KD remains uncertain. We report our findings of the vascular response of the coronary arteries to intracoronary injection of acetylcholine (ACh) in patients with KD.

Methods. A total of 35 patients (25 patients with KD and 10 control subjects) were examined using coronary angiography. Individual arteries were divided into four groups according to the type of the coronary artery lesion: group 1 consisted of 25 sites with regressed aneurysms. These aneurysms had developed in the acute stage but had subsequently regressed and demonstrated normal findings on the follow-up coronary angiogram. Group 2 consisted of 24 sites with persistent aneurysms. Group 3 involved 60 angiographically normal sites in the same patients as those in group 1 or 2. Group 4 consisted of 30 sites in control subjects who had congenital heart disease with normal coronary arteries. During coronary angiography we infused 15 μ g of ACh chloride

into the coronary artery. The lumen diameters were measured using a cine videodensitometric analyzer to study the distensibility of the coronary artery wall.

Results. The mean (\pm SD) change in diameter was an increase of $11.71 \pm 12.34\%$ in group 3 (coronary arteries without lesions in patients with KD) and $12.21 \pm 9.71\%$ in the control group, demonstrating marked vasodilation in both groups. In contrast, the changes in the regressed aneurysms of group 1 and in the persistent aneurysms of group 2 were $-2.65 \pm 12.12\%$ and $-0.08 \pm 6.51\%$, respectively, demonstrating no change or mild vasoconstriction. The change in groups 1 and 2 was significantly less than that in group 3 or in the control group. Group 3 showed no significant difference from the control group.

Conclusions. These findings suggest that long-term coronary artery lesions, even after aneurysm regression, may have impaired endothelial function. A long-term follow-up study for those patients is essential.

(J Am Coll Cardiol 1998;31:1074-80)

©1998 by the American College of Cardiology

Coronary artery aneurysms develop in 10% to 20% of patients with acute Kawasaki disease (KD) (1). We have reported that 50% of patients with coronary aneurysms demonstrated regression of the aneurysms on follow-up coronary angiography, with completely normal findings (2). The histopathologic findings of a regressed aneurysm include marked thickening in the intima with proliferation of smooth muscle cells (3). These histopathologic changes were similar to findings in arteriosclerosis. However, the vascular function of these regressed lesions has remained uncertain.

Acetylcholine (ACh) has been reported to dilate normal coronary arteries by promoting the release of vasorelaxant

substances such as nitric oxide from the endothelium (4). In coronary arteriosclerosis, endothelium-dependent vasodilation is impaired, and paradoxical vasoconstriction has been demonstrated by ACh (5). In this study, we evaluated the vascular function of long-term coronary artery lesions in patients with KD, using an intracoronary infusion of ACh.

Methods

Study subjects. From June 1995 to August 1996, a total of 35 patients received coronary artery angiography before and after intracoronary infusion of ACh. The study group consisted of 25 patients with KD (17 boys and 8 girls) and 10 patients with congenital heart disease as control subjects. The patients had suffered from KD from 5 months to 4.4 years of age (mean 1.5 years) and have been followed for 13.4 ± 3.8 years at Kurume University Hospital. Coronary angiography was first performed for each patient with KD just after the acute stage of the illness to evaluate coronary artery lesions. The follow-up coronary angiographic study was done 1 to 12 years after the first coronary angiogram. The 25 patients with KD consisted of

From the Department of Pediatrics and the Cardiovascular Research Institute, Kurume University School of Medicine, Kurume, Japan. This study was supported in part by Research Grant 6454310 from the Ministry of Education, Tokyo, Japan.

Manuscript received October 31, 1996; revised manuscript received December 17, 1997, accepted December 30, 1997.

Address for correspondence: Dr. Hirohisa Kato, Department of Pediatrics, Kurume University School of Medicine, 67 Asahi-machi, Kurume 830, Japan. E-mail: hkato@kurume.ktarn.or.jp.

Abbreviations and Acronyms

ACh = acetylcholine
 KD = Kawasaki disease

13 with regressed coronary aneurysms, as demonstrated by normal coronary angiographic findings within 1 to 2 years, and 12 with persistent coronary aneurysms. Patients with coronary artery stenosis were excluded from the study. All patients with KD received 30 mg/kg body weight per day of aspirin during the acute stage of the illness, which was reduced to 5 mg/kg per day while the patient demonstrated abnormal coronary angiographic findings. No high dose gamma globulin was given to the patients in this study, because all patients had KD before the first report of this treatment (6).

As a control group, 10 patients (mean age 13.1 ± 2.4 years, matched to the mean age of the patients with KD) with congenital heart disease were included in this study: three with a small ventricular septal defect, five with a patent ductus arteriosus and two with mild pulmonic stenosis. All of these control subjects had normal coronary arteries on coronary angiography. Written, informed consent was obtained from the parents of all patients.

Coronary angiography. A 6F sheath was inserted percutaneously into the femoral artery, through which a 5F Judkins-Kato pediatric coronary angiography catheter was advanced up to the ostium of the right or left coronary artery using the Judkins technique. After diagnostic heart catheterization using model KXO-2050 (Toshiba Corp., Tokyo), coronary angiography was performed with injection of iohexol manually under electrocardiographic monitoring. A cardiac pacing catheter was positioned in the right ventricle to avoid bradyarrhythmias during injection of ACh. The adequate dosage of ACh required to assess vascular function is uncertain in children. Preliminarily, we studied the effects from different dosages (5, 15, 30 and 50 μg) in a normal coronary artery and in regressed coronary aneurysms in four children with KD. When we used 50 μg of ACh, the normal coronary artery became constricted, and when we used 5 μg of ACh the normal coronary artery did not dilate. When we used 15 and 30 μg of ACh, significant dilation was recognized in the normal coronary arteries, and vasoconstriction appeared in the regressed aneurysms. So, we chose a lower dose (15 μg) of ACh in this study. Thus, 15 μg of ACh chloride (Daiichi Seiyaku, Tokyo) was diluted in 5 ml of warm 0.9% saline solution (to produce a coronary blood concentration of $\sim 3.0 \times 10^{-6}$ mol/liter) and was infused through a Judkins-Kato catheter into the left coronary artery, over 30 s. The second coronary angiographic study was performed in the left coronary artery at 30 s after completion of the ACh infusion.

Study sites of coronary artery lesions. We classified our patients into four groups according to the presence or absence of coronary artery lesions (Fig. 1). Group 1 involved 25 sites of regressed coronary artery aneurysms in 13 patients. In these

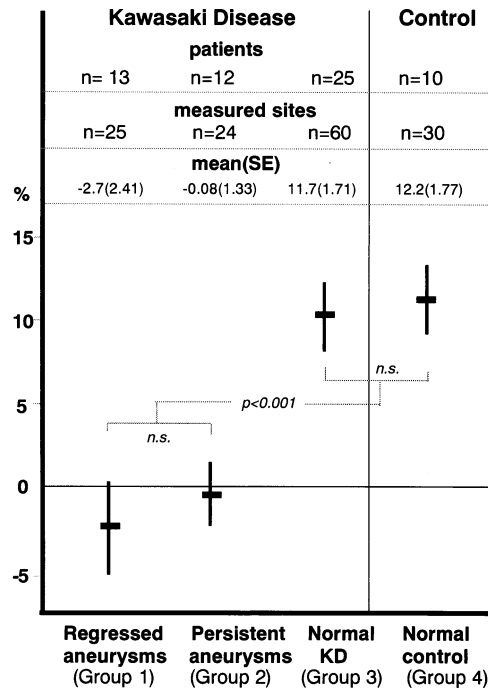


Figure 1. Percent change in coronary artery diameter after intracoronary infusion of ACh in each group. Data are presented as mean value \pm SEM.

patients, the coronary artery aneurysms in the early stage had become regressed, and on a follow-up coronary angiography 1 to 2 years later, they demonstrated normal findings. We measured the lumen diameter at the same sites at the point where the maximal diameter of the aneurysms had existed in the acute stage of KD. Group 2 involved 24 sites of persistent coronary aneurysms in 12 patients. Group 3 involved 60 angiographically normal sites of the coronary artery in the same 25 patients with KD as those in group 1 or 2, who had either regression or persistence of aneurysms. In these patients we chose other normal sites where coronary aneurysms had not developed in the acute stage of KD and also demonstrated normal findings at follow-up coronary angiography. These normal sites included coronary segments located at least 10 mm from the site of previous aneurysms or opposite a previous aneurysm site, which is normal for a coronary artery during the acute phase of KD. Group 4 involved 30 sites in 10 patients (control group) with congenital heart disease who demonstrated normal coronary angiographic findings.

Angiographic analysis. We measured the lumen diameter of several sites with large- or moderate-sized left coronary arteries in the same patient, such as in the main trunk of the left coronary artery, the left anterior descending coronary artery, the left circumflex artery and the main right coronary artery, where coronary aneurysms in KD are likely to develop. For measurement, we used a cine frame at the end-diastolic phase. The lumen diameters were measured using a cine analysis system computer (CARDIO-500, Kontron Elektronik, Germany) for delineation of the coronary cineangiograms.

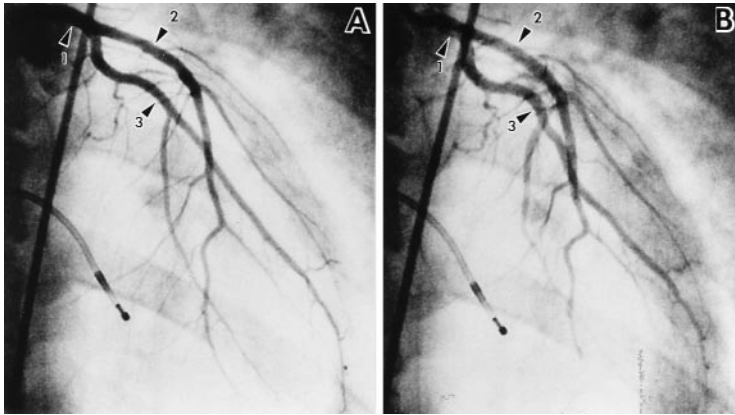


Figure 2. Coronary angiograms of the left coronary artery before (A) and after (B) injection of ACh in a child with small patent ductus arteriosus and a normal coronary artery. The coronary artery was significantly dilated with ACh infusion at the sites in the left main coronary artery, the left anterior descending coronary artery and the left circumflex artery (arrows 1, 2 and 3, respectively).

Representative angiograms of a left coronary artery before and after ACh infusion are shown in Figures 2, 3 and 4. Each site was measured three times, and the mean value was used for statistical analysis. A change in the coronary artery diameter was calculated using the following formula: percent change of each segment = (diameter after infusion - diameter before infusion)/diameter before infusion \times 100. The percent change in each patient was defined as the mean percent change of overall segments.

Statistical analysis. Analysis of variance for repeated measurements with the Bonferroni correction was used to compare the groups. The Student *t* test was used for two-way comparison of data, and $p < 0.05$ was considered significant. Previous studies reported that different segments of the coronary arteries had different responses to ACh (7,8). Therefore, in each group we calculated the percent change in each segment, independent of the subjects from which they were taken, and compared this percent change in each segment among the groups. To support our assumption that each segment in the same patient behaves independently, we also compared the percent change in each patient, which we calculated by taking the average of these percent changes in each segment in the same patient.

Results

Changes in coronary artery lumen diameter. The percent change in the coronary artery diameter in each group is shown

in Figure 1 and Table 1. The mean (\pm SD) changes in the coronary artery diameter in each segment were $-2.65 \pm 12.12\%$ in the regressed aneurysms of group 1, $-0.08 \pm 6.51\%$ in the persistent aneurysms of group 2, $11.71 \pm 12.34\%$ in the angiographically normal sites of group 3 and $12.21 \pm 9.71\%$ in group 4 (control). The persistent aneurysms of group 2 demonstrated almost no change in the lumen diameter and significantly less change than that in the control group ($p < 0.001$) or the group with normal sites ($p < 0.001$). In group 1 with regressed aneurysms, mild vasoconstriction was recognized, which was significantly different from that in group 3 with normal sites ($p < 0.001$) or group 4 (control) ($p < 0.001$). No significant difference was recognized between the regressed aneurysms of group 1 and the persistent aneurysms of group 2. There were no significant differences between groups 2 and 4. The percent changes in overall segments of the coronary artery in each patient were $-4.32 \pm 11.07\%$ in group 1, $-0.30 \pm 5.80\%$ in group 2, $11.49 \pm 7.10\%$ in group 3 and $12.19 \pm 6.35\%$ in group 4. Significantly less change was not noted in group 4 ($p < 0.001$) and group 3 ($p < 0.001$). In group 1, there was a significant difference due to mild vasoconstriction, as compared with group 3 ($p < 0.001$) and group 4 ($p < 0.001$). There was no significant difference between groups 1 and 2. There was no significant difference between groups 3 and 4. A similar trend still existed after the mean percent change in overall segments of the coronary artery in each patient was used to eliminate effects due to multiple points from the same patient. To support our assumption that each segment in the same

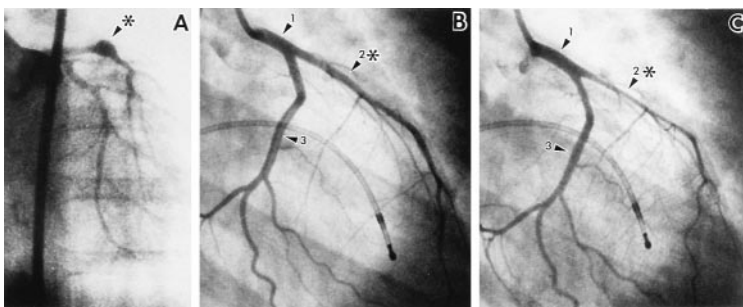
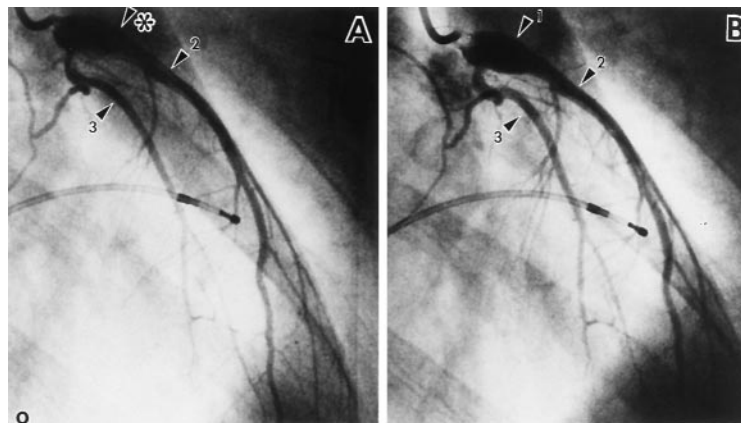


Figure 3. Coronary angiograms of the left coronary artery in a patient with regressed coronary aneurysms. A, This boy had an aneurysm (arrowhead with asterisk) in the left anterior descending coronary artery in the acute stage of KD (at 1.6 years of age), which subsequently regressed. B, Twelve years later, a coronary angiogram demonstrated a regressed aneurysm (arrowhead 2 with asterisk) that showed normal findings before ACh infusion. C, After infusion of ACh, significant vasoconstriction at the site of the regressed coronary aneurysm was demonstrated (arrowhead 2 with asterisk) (decreased by 25% in diameter). The sites of the intact coronary artery (arrowheads 1 and 3) demonstrated mild vasodilation (increased in diameter by 8% and 5%, respectively).

Figure 4. This patient was affected by KD at 4 years of age and developed an aneurysm in the left anterior descending coronary artery. Coronary angiograms at 18 years of age before (A) and after (B) injection of ACh demonstrated no change of the lumen diameter at the site of a persistent aneurysm (arrowhead 1 with asterisk). However, the normal sites of the coronary artery demonstrated mild dilation (arrowheads 2 and 3).



patient behaves independently, we also compared the percent change in each patient, which we calculated by taking the average of these percent changes in each segment in the same patient.

Complications. The heart rate and aortic pressure did not change during this study. Changes in the ST segment were observed on the electrocardiograms of four patients during intracoronary infusion of ACh, but lasted only a few seconds. All patients had no chest pain, no palpitations and no arrhythmias during or after infusion of ACh.

Discussion

The long-term prognosis and natural history of KD, particularly in patients with normal coronary arteries or regressed coronary aneurysms, remains uncertain at the present time. We have reported that >50% of aneurysms regress within several years and demonstrate normal angiographic findings (9). However, on histologic examination, marked thickening of the intima is found, which may be caused by the proliferation of smooth muscle cells. This proliferation may then produce the normal-sized lumen in the coronary artery (3,10). Intravascular ultrasound imaging of the sites of regressed coronary aneurysms has also demonstrated intimal thickening (11). These findings are similar to those found in arteriosclerosis. In this study we evaluated the vascular function of the coronary artery after KD using intracoronary injection of ACh. Acetylcholine is believed to dilate normal blood vessels by promoting the release of vasorelaxant substances such as nitric oxide (12). In contrast, if the endothelial function is impaired, ACh directly causes medial smooth muscle constriction. In coronary arteriosclerosis, endothelium-dependent vasodilation is impaired and paradoxical vasoconstriction is induced by ACh (13).

In the present study, the normal sites of group 3 and control sites of group 4 demonstrated marked vasodilation due to ACh administration, which suggested that these lesions had normal endothelial function. The sites of the persistent aneurysms of group 2 presented an abnormal response to ACh and showed no change or mild vasoconstriction of the coronary artery. Even after regression of aneurysms, as indicated by angio-

graphically normal findings, the responses to ACh at these sites showed mild vasoconstriction of the coronary artery or weak dilation in several patients. These responses suggested that the coronary artery had impaired endothelium-dependent relaxation in the sites of aneurysm regression after KD. To further assess the endothelial function, the vascular responses of sites with lesions to isosorbide dinitrate, in addition to ACh, should be studied. If only the endothelium is impaired, ACh should cause paradoxical vasoconstriction and isosorbide dinitrate should produce vasodilation. In this study we did not inject ACh and isosorbide dinitrate concurrently, and this is a limitation of our study. However, we previously investigated the ability of the coronary artery to dilate with intracoronary infusion of isosorbide dinitrate after KD (14). In the group with persistent aneurysms or stenosis, the mean observed dilation was significantly less than that in the group with normal coronary arteries. In the present study those lesions with persistent coronary aneurysms demonstrated almost no changes with ACh infusion. These two results suggest that a portion of the persistent coronary aneurysms may have had increased coronary arterial stiffness. In the patients with regressed aneurysms, the coronary artery was dilated using isosorbide dinitrate, although the coronary artery was dilated more in the control group. Our studies suggest that the regressed coronary artery showed pathologically abnormal responses to ACh and may have endothelial dysfunction with impairment in endothelium-dependent vasodilation. Smooth muscle dysfunction may also be present.

In this study, as the unit of analysis, we used the lesion of the coronary artery instead of the patient, because the aim of our study was to evaluate the vascular function of different lesions such as regressed aneurysms, persistent aneurysms and angiographically normal sites in the same patient. As shown in Figure 3, as a representative case, the lesion of the regressed aneurysm demonstrated marked vasoconstriction, whereas the portion of the intact coronary artery in the same patient revealed paradoxical vasodilation. Also, in the patient shown in Figure 4, the site of persistent coronary aneurysm demonstrated no change with ACh infusion, but the portion with angiographically normal findings showed dilation of the arter-

Table 1. Percent Changes in Coronary Artery Lumen Diameter in Response to Acetylcholine

Pt. No.	Group 1*			Group 2†			Group 3‡			Group 4§		
	Site	Δ in Segment	Mean Δ in Each Patient	Site	Δ in Segment	Mean Δ in Each Patient	Site	Δ in Segment	Mean Δ in Each Patient	Site	Δ in Segment	Mean Δ in Each Patient
1	S5	7.77	5.01				S1	11.50	14.43			
	S6	2.26					S2	15.57				
2	S5	-9.76	-12.88				S1	3.82	3.51			
	S6	-16.00					S2	2.34				
3	S1	8.11	9.33				S3	4.36	25.34			
	S3	10.55					S5	38.50				
4	S1	-10.10	-7.95				S7	21.83	8.18			
	S2	-7.31					S13	15.69				
5	S3	-6.43	-25.00				S5	5.23	4.96			
	S1	-25.00					S7	8.23				
6	S2	4.38	3.63				S11	1.43	21.76			
	S6	12.92					S1	22.63				
7	S7	-6.41	-14.80				S3	20.89	2.85			
	S6	-14.80					S1	1.35				
8	S5	12.17	5.36				S2	1.24	17.13			
	S6	12.82					S3	5.95				
9	S3	-8.92	8.83				S7	15.93	7.19			
	S5	8.83					S13	18.33				
10	S5	-10.80	-2.05				S1	7.99	3.93			
	S1	6.70					S2	22.22				
11	S3	-14.00	-14.00				S3	21.20	7.19			
							S2	7.86				
12	S1	-16.79	-14.30				S7	0.00	13.38			
	S2	-11.81					S5	2.10				
13	S1	9.30	2.65				S6	5.75	10.20			
	S2	-4.00					S7	13.71				
Mean		-2.65	-4.32				S5	23.95				
							S6	2.81				
							S5	16.03				
							S6	4.36				
14				S5	-11.06		S1	1.29				
				S6	-10.50	-10.78	S2	1.34	1.32			
15				S6	0.08		S1	5.03				
				S11	-8.84	-4.38	S2	21.00	13.02			
16				S1	0.90		S5	16.67				
						0.90	S6	19.35				
							S7	20.29	18.77			
17				S1	9.30		S5	28.22				
				S2	12.05		S6	26.48				
						10.68	S7	28.83	27.84			
18				S5	-1.51		S7	13.59				
				S6	-5.14	-3.33	S13	7.93	10.76			
19				S5	12.87		S7	15.73				
				S6	-0.20		S13	5.90				
				S11	0.08	4.25			10.82			
20				S5	6.89		S1	10.97				
				S6	2.36							
				S7	-1.52	2.58			10.97			
21				S1	-1.02		S5	9.20				
				S2	2.51	0.75	S6	12.86	11.03			
22				S2	-4.94		S5	1.19				
				S3	-3.50	-4.22	S6	22.57	11.88			

Table 1. (continued).

Pt. No.	Group 1*			Group 2†			Group 3‡			Group 4§		
	Site	Δ in Segment	Mean Δ in Each Patient	Site	Δ in Segment	Mean Δ in Each Patient	Site	Δ in Segment	Mean Δ in Each Patient	Site	Δ in Segment	Mean Δ in Each Patient
23				S2	6.07		S1	16.44				
				S6	5.62		S3	21.33				
						5.85	S7	3.82	13.86			
24				S2	-4.33		S3	1.76				
				S6	-6.93	-5.63	S13	1.91	1.76			
25				S6	-1.27		S2	11.21				
							S3	1.50				
Mean						-1.27	S13	2.95	5.22			
					-0.08	-0.30		11.71	11.49			
26										S1	15.00	
										S5	16.30	
										S6	15.47	15.59
27										S1	3.09	
										S2	4.42	
										S6	3.89	3.80
28										S1	27.00	
										S5	13.87	
										S6	12.50	17.79
29										S2	20.18	
										S3	20.75	
										S6	17.24	19.39
30										S1	21.34	
										S3	16.60	
										S11	10.81	16.25
31										S2	5.94	
										S3	22.81	
										S6	21.07	16.61
32										S1	1.60	
										S5	1.32	
										S6	1.39	1.44
33										S2	6.11	
										S3	5.65	
										S6	6.00	5.92
34										S1	12.30	
										S2	10.41	
										S6	9.66	10.79
35										S5	13.60	
										S6	15.03	
										S7	14.84	14.29
Mean										12.21	12.19	

*Group 1 with regressed aneurysms. †Group 2 with persistent aneurysms. ‡Group 3 with normal coronary arteries. §Group 4 as control group. Data are presented as the percent change in coronary artery diameter. Pt. = patient; S1 to S13 = segment of the coronary artery according to the American Heart Association Committee Report; Δ = change.

ies. For the group with normal coronary arteries (group 3) and the control group (group 4), we measured several sites of coronary arteries in the same subject, assuming that each segment in the same patient behaves independently, because previous reports revealed that different segments of the coronary arteries had different responses to ACh (7,8). These different responses in each segment, however, may not directly explain the independence of the response. Hence, we also compared the vascular response using the mean percent change in overall segments of the coronary artery in each patient to eliminate the potential problem of multiple mea-

surements in the same patient, and we found the same trend. These findings suggested that the response or behavior to ACh varied independently in the different lesions of the coronary arteries in the same patient. We believe that such endothelial dysfunction does not exist uniformly in all of the coronary arteries after KD, and that the endothelial function of coronary arteries should be considered in each lesion of the arteries. Based on this reasoning, the unit of statistical analysis of this study was the coronary artery lesion and not the patient. In the control group with normal coronary arteries, we measured several sites of the coronary arteries in the same subject,

because there were no data on the vascular response to ACh in the different portions of the normal coronary artery in children. Because this resulted in almost identical behavior in response to ACh, we used these patients' mean value for statistical analyses.

At the sites of persistent coronary aneurysms, the diameter of the vascular lumen did not change with ACh infusion. These sites did not demonstrate marked dilation or marked constriction in the sites of coronary aneurysms. These findings suggest that both impaired endothelial function and smooth muscle dysfunction, or increased coronary arterial stiffness, contributed to this phenomenon. We excluded patients with stenotic lesions in the coronary artery from this study to avoid causing unnecessary ischemic events due to constriction of such lesions during ACh infusion.

In this study, the sites of normal coronary arteries in patients with KD, where coronary aneurysms had not developed at the acute stage and which had demonstrated normal coronary angiographic findings on follow-up, responded normally to ACh. These findings suggest that these portions of the coronary arteries had normal endothelial function. However, it should be mentioned that Mitani et al. (15) described that a normal portion of the coronary artery after KD constricted due to ACh infusion, although the number of patients they studied was small. We should further investigate patients with normal coronary arteries who did not develop coronary aneurysms from acute KD.

Long-term clinical implications. It is evident that coronary artery lesions after long-term KD have impaired endothelial function. However, it is uncertain how long it persists or whether it gradually improves over time. In this study we did not compare the vascular response to ACh in the same patient over time; however, we speculate that this endothelial dysfunction may persist longer and may develop into arteriosclerosis. Long-term follow-up is necessary, not only for patients with abnormal coronary lesions but also for patients with regressed aneurysms. It has been reported that most angiographically normal coronary arteries in subjects >30 years old have endothelial dysfunction, as demonstrated by an abnormal response to ACh, and therefore have a risk for developing early coronary arteriosclerosis (7). A long-term follow-up study

of patients with KD should focus on the possible development of arteriosclerosis and ischemic heart disease in adulthood.

References

1. Kato H, Ichinose E, Yoshioka F, Takechi T, Matsunaga S, Suzuki K, Rikitake N. Fate of coronary aneurysms in Kawasaki disease: serial coronary angiography and long-term follow-up study. *Am J Cardiol* 1982;49:1758-66.
2. Kato H, Koike S, Yamamoto M, Ito U, Yano E. Coronary artery aneurysms in infants and young children with acute febrile mucocutaneous lymph node syndrome. *J Pediatr* 1975;86:892-8.
3. Sasaguri Y, Kato H. Regression of aneurysms in Kawasaki disease: a pathological study. *J Pediatr* 1982;100:225-31.
4. Palmer RM, Ferrige AG, Moncada S. Nitric oxide release accounts for the biological activity of endothelium-derived relaxing factor. *Nature* 1987;327:524-6.
5. Ludmer PL, Selwyn AP, Shook TL, et al. Paradoxical vasoconstriction induced by acetylcholine in atherosclerotic coronary arteries. *N Engl J Med* 1986;315:1046-51.
6. Furusho K, Kamiya T, Nakano H, et al. High-dose intravenous gammaglobulin for Kawasaki disease. *Lancet* 1984;2:1055-8.
7. Yasue H, Matsuyama K, Matsuyama K, Okumura K, Morikami Y, Ogawa H. Responses of angiographically normal human coronary arteries to intracoronary injection of acetylcholine by age and segment: possible role of early coronary atherosclerosis. *Circulation* 1990;81:482-90.
8. Newman CM, Maseri A, Hackett DR, El-Tamimi HM, Davies GJ. Responses of angiographically normal and atherosclerotic left anterior descending coronary arteries to acetylcholine. *Am J Cardiol* 1990;66:1070-6.
9. Kato H, Sugimura T, Akagi T, et al. Long-term consequences of Kawasaki disease: a 10- to 21-year follow-up study of 594 patients. *Circulation* 1996;94:1121-8.
10. Fujiwara T, Fujiwara H, Nakano H. Pathological features of coronary arteries in children with Kawasaki disease in which coronary arterial aneurysm was absent at autopsy. *Circulation* 1988;78:345-50.
11. Sugimura T, Kato H, Inoue O, et al. Intravascular ultrasound of coronary arteries in children: assessment of the wall morphology and the lumen after Kawasaki disease. *Circulation* 1994;89:258-65.
12. Hodgson JM, Marshall JJ. Direct vasoconstriction and endothelium-dependent vasodilatation. *Circulation* 1989;79:1043-51.
13. Egashira K, Inoue T, Hirooka Y, Yamada A, Urabe Y, Takeshita A. Evidence of impaired endothelium-dependent coronary vasodilatation in patients with angina pectoris and normal coronary angiograms. *N Engl J Med* 1993;328:1659-64.
14. Sugimura T, Kato H, Inoue O, Takagi J, Fukuda T, Sato N. Vasodilatory response of the coronary arteries after Kawasaki disease: evaluated by intracoronary injection of isosorbide dinitrate. *J Pediatr* 1992;121:684-8.
15. Mitani Y, Okuda Y, Inoue M, Aoki K, Sakurai M. Impaired endothelium-dependent relaxation of angiographically normal coronary arteries in patients after Kawasaki disease in the long-term follow-up period. In: *Kawasaki Disease*. Kato H, editor. Amsterdam: Elsevier Science, 1995:578-91.