

# The Site of Plaque Rupture in Native Coronary Arteries

## A Three-Vessel Intravascular Ultrasound Analysis

Myeong-Ki Hong, MD,\* Gary S. Mintz, MD, FACC,‡ Cheol Whan Lee, MD,\* Bong-Ki Lee, MD,\*  
Tae-Hyun Yang, MD,\* Young-Hak Kim, MD,\* Jong-Min Song, MD,\* Ki-Hoon Han, MD,\*  
Duk-Hyun Kang, MD,\* Sang-Sig Cheong, MD,† Jae-Kwan Song, MD, FACC,\* Jae-Joong Kim, MD,\*  
Seong-Wook Park, MD, FACC,\* Seung-Jung Park, MD, FACC\*

*GangNeung and Seoul, Korea; and New York, New York*

<b>OBJECTIVES</b>	We evaluated the axial location of plaque ruptures in native coronary arteries.
<b>BACKGROUND</b>	It is clinically important to understand the potential sites of plaque rupture.
<b>METHODS</b>	We performed three-vessel intravascular ultrasound (IVUS) examination in 392 patients; 231 had acute coronary syndrome (ACS) and 161 had stable angina pectoris (SAP). The IVUS detected plaque ruptures in 206 patients: 158 ACS patients and 48 SAP patients. The distance between each coronary plaque rupture segment and the respective coronary ostium was measured with motorized IVUS transducer pullback in all three coronary arteries.
<b>RESULTS</b>	There were a total of 273 plaque ruptures in these 206 patients; 143 in the left anterior descending artery (LAD), 40 in the left circumflex artery (LCX), and 90 in the right coronary artery (RCA). There were 67 plaque ruptures in SAP patients and 206 in ACS patients; there were 197 culprit/target lesion plaque ruptures and 76 non-culprit/non-target lesion plaque ruptures. The LAD plaque ruptures were predominantly located between 10 and 40 mm from the LAD ostium (83%, 119 of 143). The LCX plaque ruptures were evenly distributed in the entire LCX tree. Most RCA plaque ruptures were located in segments between 10 and 40 mm (48%, 43 of 90) and in segments >70 mm from the ostium (32%, 29 of 90).
<b>CONCLUSIONS</b>	Three-vessel IVUS imaging showed that plaque ruptures occurred mainly in proximal segments of the LAD (83% of LAD plaque rupture), the proximal and distal segments of the RCA (48% and 32% of RCA plaque ruptures, respectively), and the entire LCX. (J Am Coll Cardiol 2005;46:261-5) © 2005 by the American College of Cardiology Foundation

Recent angiographic study showed that acute coronary occlusion leading to ST-segment elevation myocardial infarction (MI) tended to cluster within the proximal third of each of the coronary arteries (1). Not all acute coronary occlusions are the result of plaque rupture, however; some are the result of plaque erosion (2,3). And not all plaque ruptures lead to thrombosis and acute occlusion (3,4). The current study used intravascular ultrasound (IVUS) to evaluate the predilection site of culprit and non-culprit plaque rupture in all three native coronary arteries in patients with and without acute coronary syndrome (ACS).

### METHODS

**Study population.** A prospective, but nonconsecutive series of 392 patients who were scheduled for coronary intervention underwent three-vessel IVUS examination. Two hundred thirty-one had ACS and 161 had stable

angina pectoris (SAP). The frequency of culprit and non-culprit lesion plaque rupture in the first 235 patients undergoing three-vessel IVUS imaging was previously reported (5). Definitions of acute MI and SAP, identification of culprit/target lesions, and exclusion criteria for three-vessel IVUS imaging were described previously (5). At least one IVUS-detectable plaque rupture was present in 206 of the overall cohort of 392 patients. Among the 206 patients with at least one IVUS-detectable plaque rupture, there were 158 ACS patients (including 99 ST-segment elevation MI, 37 non-ST-segment elevation MI, and 22 Braunwald classification IIIB ACS patients) and 48 SAP patients. All patients provided written informed consent, and approval of the ethics committee was obtained.

**IVUS imaging and analysis.** The IVUS examinations of all three major epicardial arteries were performed before intervention and after intra-coronary administration of 0.2 mg nitroglycerin with motorized transducer pullback system (0.5 mm/s) and a commercial scanner (Boston Scientific Corp./SCIMED, Natick, Massachusetts) consisting of a rotating 30 MHz transducer within a 3.2-F imaging sheath. After successful pre-interventional imaging and treatment of the culprit/target lesion, pre-intervention IVUS exami-

From the Department of Medicine, University of Ulsan College of Medicine, Asan Medical Center, \*Seoul and †GangNeung, Korea; and the ‡Cardiovascular Research Foundation, New York, New York. This study was partly supported by the Cardiovascular Research Foundation, Seoul, Korea, and a grant from the Korea Health 21 R&D Project, Ministry of Health and Welfare, Korea (0412-CR02-0704-0001).

Manuscript received October 25, 2004; revised manuscript received March 22, 2005, accepted March 29, 2005.

**Abbreviations and Acronyms**

- ACS = acute coronary syndrome
- CSA = cross-sectional area
- EEM = external elastic membrane
- IVUS = intravascular ultrasound
- LAD = left anterior descending artery
- LCX = left circumflex artery
- MI = myocardial infarction
- RCA = right coronary artery
- SAP = stable angina pectoris

nations of the remaining non-culprit/non-target arteries and lesions were performed before any additional treatment.

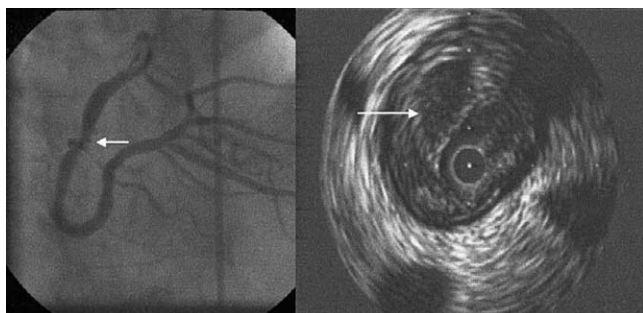
Qualitative and quantitative analyses were performed according to criteria of the Clinical Expert Consensus Document on IVUS (6).

The IVUS criteria for plaque rupture were a plaque containing a cavity that communicated with the lumen with an overlying residual fibrous cap fragment (7). A typical example of plaque rupture is shown in Figure 1. The diagnosis of plaque rupture required independent review and agreement by two of the authors (M-K.H. and Y-H.K.). Confirmation of the initial 279 plaque ruptures by a second reader and repeat evaluation by the first reader resulted in 6 plaque ruptures being excluded from this study.

In all three coronary arteries in each of the patients studied, the transducer was advanced into the distal coronary artery; and an imaging run was performed back to the aorto-ostial junction. With motorized transducer pullback, we measured the distance from each plaque rupture back to the respective coronary ostium (pullback speed multiplied by number of seconds).

Quantitative IVUS analysis was performed with computerized planimetry at the plaque rupture site. Quantitative measurements included external elastic membrane and lumen cross-sectional area (CSA). The intraplaque cavity CSA was measured (8).

**Statistical analysis.** Statistical analysis was performed with SPSS program (SPSS Inc., Chicago, Illinois). Data are presented as frequencies or mean ± 1 SD. Comparison was performed with unpaired Student *t* test and chi-square test. A *p* value <0.05 was considered statistically significant.



**Figure 1.** Angiographic and intravascular ultrasound image of a typical ruptured plaque (arrow) in a right coronary artery are shown.

**Table 1.** Baseline Clinical Characteristics of 206 Patients

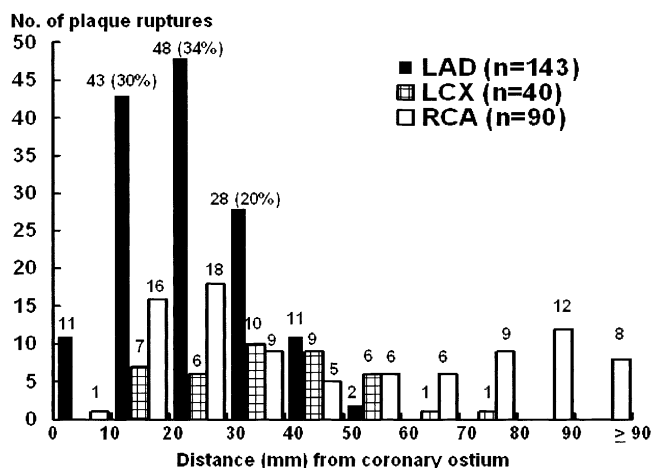
Age (yrs)	57 ± 10
Male gender	170 (83%)
Hypertension	84 (41%)
Diabetes mellitus	43 (21%)
Cigarette smoking	100 (49%)
Hypercholesterolemia (total cholesterol ≥220 mg/dl)	34 (17%)
Number of diseased vessels	
1	94 (46%)
2	68 (33%)
3	44 (21%)

**RESULTS**

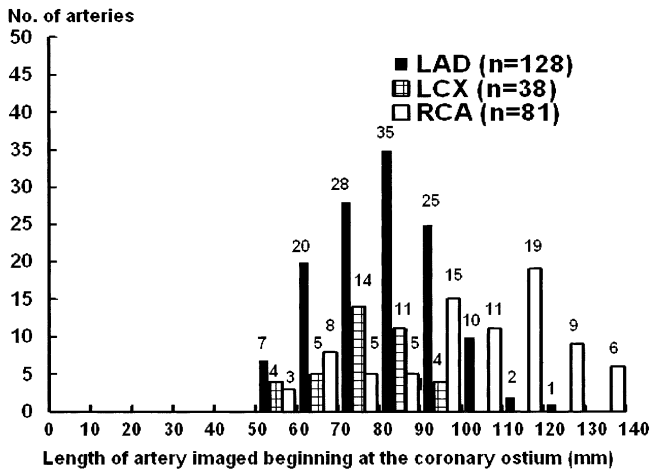
Baseline clinical characteristics of the 206 patients are shown in Table 1. Multiple plaque ruptures (≥2 plaque ruptures) were observed in 53 patients (40 ACS patients and 13 SAP patients). Thus, a total of 273 plaque ruptures were detected in 247 coronary arteries: 143 ruptures in 128 left anterior descending arteries (LAD), 40 ruptures in 38 left circumflex arteries (LCX), and 90 ruptures in 81 right coronary arteries (RCA) (Fig. 2). In these 247 arteries with at least one plaque rupture, the total length of the coronary artery imaged by IVUS was 83 ± 14 mm in the LAD, 77 ± 12 mm in the LCX, and 101 ± 22 mm in the RCA.

As illustrated in Figure 3, at least the proximal 50 mm of each of the three arteries was imaged in each patient. The frequency of plaque ruptures located in segments 0 to 30 mm, 30 to 60 mm, 60 to 90 mm, and >90 mm from the coronary ostium when these corresponding segments were actually imaged (thereby, excluding segments that could not be reached with the IVUS catheter) were 61% (150 of 247), 35% (86 of 247), 13% (29 of 233), and 8% (8 of 102), respectively (*p* <0.001).

A LAD plaque rupture was predominantly located in the segment between 10 and 40 mm from the LAD ostium (83%, 119 of 143). The LCX plaque ruptures were evenly distributed throughout the length of the LCX that was imaged. Most RCA plaque ruptures were located in the



**Figure 2.** The frequency of 273 plaque ruptures according to distance from each coronary ostium is shown for the left anterior descending artery (LAD), left circumflex artery (LCX), and right coronary artery (RCA).



**Figure 3.** The length of coronary artery containing each plaque rupture imaged with intravascular ultrasound is shown. Abbreviations as in Figure 2.

segments between 10 and 40 mm (48%, 43 of 90) and in the segments beyond 70 mm from the RCA ostium (32%, 29 of 90). This is also illustrated in Figure 2.

There were 197 culprit/target lesion plaque ruptures and 76 non-culprit/non-target lesion plaque ruptures (Fig. 4). The clustering of the plaque ruptures was similar in culprit/target lesions compared with non-culprit/non-target lesions. Quantitative IVUS measurements at ruptured plaque sites comparing culprit/target lesions and non-culprit/non-target lesions are shown in Table 2. Thrombi were found in 129 culprit/target (66%) versus 21 non-culprit/non-target lesions (28%) ( $p < 0.001$ ).

There were 206 plaque ruptures in ACS patients and 67 plaque ruptures in SAP patients. The clustering of plaque ruptures, similar to the total cohort, was also similar between ACS and SAP patients. Table 3 shows quantitative IVUS ruptured plaque segment measurements, comparing ACS and SAP patients.

Angiographic appearance was normal in 16 lesions (6%), hazy in 8 (3%), and revealed aneurysm/ulceration in 26 (10%), simple stenosis in 44 (16%), and complex stenosis in

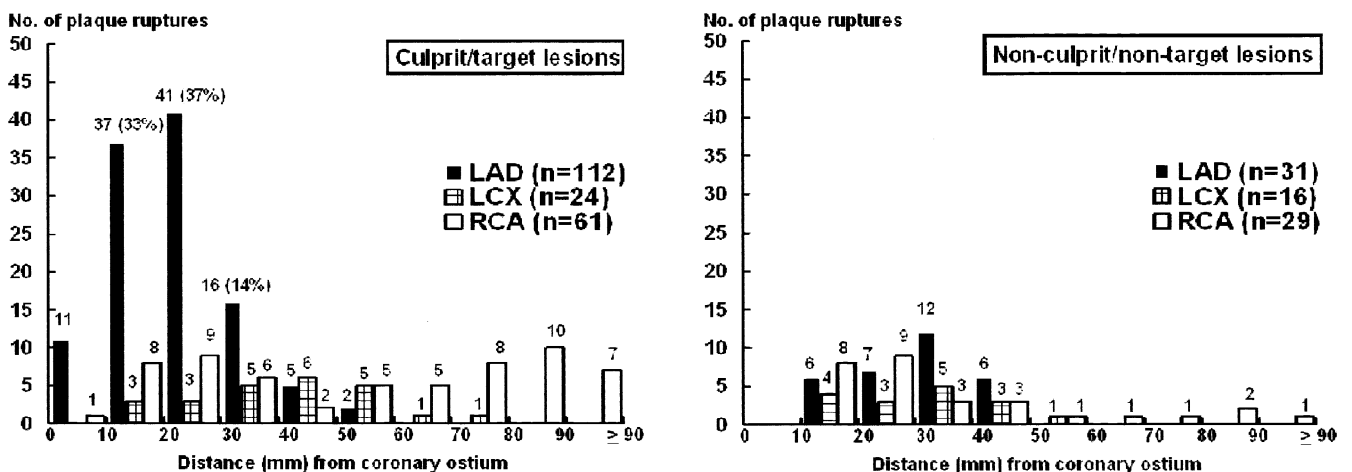
179 (65%). Plaque ruptures were located at areas of high shear stress: 136 lesions (50%) near a branch point and 31 lesions (11%) on an angulated point.

## DISCUSSION

With three-vessel IVUS imaging, we evaluated the geographic distribution of both culprit/target lesion plaque rupture as well as non-culprit/non-target lesion plaque ruptures in native coronary arteries in 395 patients with both ACS and SAP. Plaque ruptures—especially culprit/target lesion plaque ruptures—were clustered mainly in the proximal segments of the LAD, in the proximal and distal segments of the RCA, and in the entire LCX.

In a recent angiographic study, Wang et al. (1) analyzed 208 consecutive patients with ST-segment elevation MI to determine the location of epicardial thrombosis. These occlusions tended to cluster within the proximal third of each coronary artery. The current study agrees with Wang et al. regarding the proximal distribution of LAD (83%) and RCA (48%) plaque ruptures; however, in the current study, 32% of RCA plaque ruptures were >70 mm from the RCA ostium, and there was no predilection for LCX plaque rupture to develop at any one specific location. The reasons for the differences between the current IVUS study and the previous angiographic study are unclear, but the study populations were different, and the number of LCX plaque ruptures or acute occlusions was small in both studies. The angiographic study enrolled patients with acute vessel occlusion regardless of the underlying plaque pathology (plaque rupture vs. erosion), whereas we included any plaque rupture regardless of clinical consequences. Therefore, especially in the RCA, which has few branches, the initial event may be more distal and the angiographic occlusion more proximal, following retrograde thrombus propagation.

In addition, the current study extends the findings of the angiographic study of Wang et al. (1) by also studying patients with stable angina as well as by studying secondary (non-culprit and non-target lesion) plaque ruptures. While



**Figure 4.** The frequency of plaque ruptures according to distance from each coronary ostium is shown for the LAD, LCX, and RCA. Culprit/target lesions and non-culprit/non-target lesions are shown separately. Abbreviations as in Figure 2.

**Table 2.** Quantitative IVUS Measurements at Ruptured Plaque Segments Between Culprit/Target Lesions and Non-Culprit/Non-Target Lesions

	Culprit/Target Lesions	Non-Culprit/Non-Target Lesions	p Value
Number of lesions	197	76	
EEM CSA (mm <sup>2</sup> )	16.0 ± 4.0	16.1 ± 4.6	0.8
Lumen CSA (mm <sup>2</sup> )	2.7 ± 0.9	4.8 ± 2.2	<0.001
Intra-plaque cavity CSA (mm <sup>2</sup> )	2.4 ± 0.8	2.1 ± 0.8	0.025
Distance from the ostium (mm)			
Left anterior descending artery	84 ± 14	82 ± 12	0.6
Left circumflex artery	78 ± 11	72 ± 13	0.06
Right coronary artery	104 ± 19	100 ± 27	0.4

CSA = cross-sectional area; EEM = external elastic membrane; IVUS = intravascular ultrasound.

**Table 3.** Quantitative IVUS Measurements at Ruptured Plaque Segments Between ACS and SAP

	ACS	SAP	p Value
No. of culprit/target lesions	153	44	
EEM CSA (mm <sup>2</sup> )	16.2 ± 4.0	15.6 ± 4.3	0.4
Lumen CSA (mm <sup>2</sup> )	2.7 ± 0.9	2.7 ± 0.9	0.6
Intra-plaque cavity CSA (mm <sup>2</sup> )	2.3 ± 0.8	2.6 ± 1.0	0.062
No. of non-culprit/non-target lesions	53	23	
EEM CSA (mm <sup>2</sup> )	16.2 ± 4.5	16.0 ± 4.9	0.9
Lumen CSA (mm <sup>2</sup> )	4.7 ± 2.3	5.1 ± 2.2	0.5
Intra-plaque cavity CSA (mm <sup>2</sup> )	2.1 ± 0.7	2.1 ± 1.0	0.9

ACS = acute coronary syndrome; CSA = cross-sectional area; EEM = external elastic membrane; IVUS = intravascular ultrasound; SAP = stable angina pectoris.

a minority of SAP target lesions contained plaque ruptures, the locations were similar to those of ACS patients, confirming the importance of plaque rupture clustering. Multifocal plaque instability has been reported in previous studies (5,7,8). The current study showed that proximal segments of the LAD and RCA were also the most common sites of secondary plaque ruptures.

There are several possible explanations for the distribution of plaque ruptures. First, plaque rupture distribution seems to follow the distribution of coronary atherosclerosis as assessed with IVUS (9-11) as well as the larger arterial dimensions present in the proximal LAD and LCX and throughout the RCA. Second, within segments of higher plaque burden, plaque ruptures seem to occur at sites of increased stress (i.e., 50% occurred near a branch point).

**Study limitations.** This study was a single center IVUS study. Further studies will be needed to validate the current study in a larger number of patients in multiple centers. Compared with angiography, IVUS imaging is limited by distal lesion location, small vessel size, and confounding IVUS morphology (thrombus may obscure the ruptures). An IVUS cannot identify the age of a ruptured plaque cavity. The distal RCA was routinely imaged, but the distal LCX (because of tortuosity) and LAD (because of vessel tapering) were less frequently imaged. The technique of saline flushing was not routinely used in this study; it was performed to identify 41 (15%) subtle plaque ruptures. Volumetric analysis was not performed.

**Conclusions.** Three-vessel IVUS imaging in 392 patients (206 with plaque ruptures) showed that plaque ruptures occurred mainly in the proximal segments of the LAD, the proximal and distal segments of the RCA, and the entire LCX. This data may be useful in devising strategies for vulnerable (rupture-prone) plaque detection.

**Reprint requests and correspondence:** Dr. Seung-Jung Park, Department of Medicine, University of Ulsan College of Medicine, Asan Medical Center, 388-1 Poongnap-dong, Songpa-gu, Seoul, 138-736, Korea. E-mail: sjpark@amc.seoul.kr.

## REFERENCES

1. Wang JC, Normand SLT, Mauri L, Kuntz RE. Coronary artery spatial distribution of acute myocardial infarction occlusions. *Circulation* 2004;110:278-84.
2. Falk E, Shah PK, Fuster V. Coronary plaque disruption. *Circulation* 1995;92:657-71.
3. Naghavi M, Libby P, Falk E, et al. From vulnerable plaque to vulnerable patient: a call for new definitions and risk assessment strategies: part 1. *Circulation* 2003;108:1664-72.
4. Burke AP, Kolodgie FD, Farb A, et al. Healed plaque ruptures and sudden coronary death: evidence that subclinical rupture has a role in plaque progression. *Circulation* 2001;103:934-40.
5. Hong MK, Mintz GS, Lee CW, et al. Comparison of coronary plaque rupture between stable angina and acute myocardial infarction: a three-vessel intravascular ultrasound study in 235 patients. *Circulation* 2004;110:928-33.
6. Mintz GS, Nissen SE, Anderson WD, et al. American College of Cardiology clinical expert consensus document on standards for

- acquisition, measurement and reporting of intravascular ultrasound studies (IVUS): a report of the American College of Cardiology Task Force on Clinical Expert Consensus Documents. *J Am Coll Cardiol* 2001;37:1478-92.
7. Kotani JJ, Mintz GS, Castagna MT, et al. Intravascular ultrasound analysis of infarct-related and non-infarct-related arteries in patients who presented with an acute myocardial infarction. *Circulation* 2003;107:2889-93.
  8. Rioufol G, Finet G, Ginon I, et al. Multiple atherosclerotic plaque rupture in acute coronary syndrome: a three-vessel intravascular ultrasound study. *Circulation* 2002;106:804-8.
  9. Kapadia SR, Nissen SE, Ziada KM, et al. Development of transplantation vasculopathy and progression of donor-transmitted atherosclerosis. Comparison by serial intravascular ultrasound imaging. *Circulation* 1998;98:2672-8.
  10. Tinana A, Mintz GS, Weissman NJ. Volumetric intravascular ultrasound quantification of the amount of atherosclerosis and calcium in nonstenotic arterial segments. *Am J Cardiol* 2002;89:757-60.
  11. Bocksch W, Wellnhofer E, Klimek W, et al. Intravascular ultrasound assessment of longitudinal plaque distribution patterns in patients with angiographically silent coronary artery disease after heart transplantation. *Coron Artery Dis* 2002;13:349-56.