

Surgical Therapy for Atrial Tachycardia in Adults

MARK A. McGUIRE, MB, BS, DAVID C. JOHNSON, FRACS, GRAHAM R. NUNN, FRACS, TERESA YUNG, FRCPA, FRCPS(C), JOHN B. UTHER, MD, FRACP, DAVID L. ROSS, FRACP, FACC

Sydney, New South Wales, Australia

Eighteen adult patients with atrial tachycardia refractory to treatment with a mean of four drugs underwent attempted surgical cure. Atrial tachycardia originated in the right atrium in 17 patients and the left atrium in 1 patient. Tachycardia could be reproducibly induced and terminated by atrial extrastimuli or atrial pacing in 8 patients (44%). Resection of the arrhythmogenic area was performed in 16 patients (89%), and an isolation procedure was performed in 1 patient. In seven cases (39%), the area of isolation or excision included the sinoatrial node. One patient underwent His bundle section because the arrhythmogenic region was too close to the atrioventricular (AV) conduction system to enable resection.

The mean duration of clinical follow-up was 56 ± 34 months. Clinical tachycardia recurred in five patients

(28%), but in two patients it did not recur until >1 year after surgery. A permanent pacemaker was implanted in 3 (18%) of the 17 patients whose His-Purkinje system was left intact. One other patient had required permanent pacing before surgery. Only one of the seven patients undergoing sinoatrial node resection or isolation required permanent pacing for symptomatic bradycardia. Apart from the requirement for permanent pacing, no significant complications occurred.

Surgical therapy for atrial tachycardia is a safe procedure, but the rate of cure appears to be less than that of supraventricular tachycardias associated with accessory AV connections. Excision or isolation of the sinoatrial node does not necessitate permanent pacing in most patients.

(*J Am Coll Cardiol* 1989;14:1777-82)

Atrial tachycardia is a supraventricular tachycardia that requires atrial tissue alone for its genesis and perpetuation. It is a relatively rare arrhythmia, accounting for approximately 7% of supraventricular tachycardias investigated at electrophysiologic study (1). Atrial tachycardia is frequently refractory to drug therapy and, therefore, surgical cure is highly desirable (2). Since the first reported case of surgical cure in 1973 (3), few cases of successful surgical treatment in adults have been reported (4-9). Previous reports have described single cases or series of fewer than eight adult patients. Gillette et al. (10) reported a more substantial series of 14 pediatric patients, but there is evidence that atrial tachycardia in children may differ from the arrhythmia found in adults (4-10). Atrial tachycardia occurring in children is more commonly incessant and is usually due to enhanced automa-

ticity, whereas in many adults, the arrhythmia is paroxysmal and is often a result of reentry (4-10). Moreover, in adults, atrial tachycardia arises predominantly in the right atrium, whereas in children, a significant proportion originates in the left atrium (4-10). This report reviews our experience in 18 adult patients who underwent attempted surgical cure of atrial tachycardia.

Methods

Atrial tachycardia. This rhythm was defined as a regular supraventricular tachycardia with a rate <250 beats/min that did not require atrioventricular (AV) node or ventricular tissue for its perpetuation.

Study patients (Table 1). Eighteen patients (13 female, 5 male) underwent attempted surgical cure of atrial tachycardia between 1979 and 1988. Their mean age was 33 years (range 16 to 66). In all patients, the arrhythmia had been refractory to drug therapy. Patients had received two to five drugs (mean four) without significant improvement. The mean duration of symptoms was 12.5 ± 10.8 years. Four patients had been pregnant at the onset of symptoms. The tachycardia was paroxysmal in 10 patients and incessant in

From the Cardiology and Cardiothoracic Surgical Units, Westmead Hospital, Sydney, New South Wales, Australia. Dr. McGuire is supported by a grant from the National Health and Medical Research Council of Australia, Phillip, Australian Capital Territory, Australia.

Manuscript received December 12, 1988; revised manuscript received July 11, 1989, accepted July 26, 1989.

Address for reprints: David L. Ross, MD, Cardiology Unit, Westmead Hospital, Westmead, NSW 2145, Australia.

Table 1. Clinical Features of 18 Patients With Atrial Tachycardia

Case No.	Age (yr)/ Gender	Tachycardia	Years Present	Drugs Used Unsuccessfully	Coexistent Heart Disease
1	35/F	Paroxysmal	4	Q, D, Ds	—
2	41/F	Incessant	5	Q, Ds, V	—
3	26/M	Incessant	26	Q, D, P	—
4	23/F	Incessant	5	P, Met	—
5	38/F	Incessant	10	Met, Ds	—
6	19/F	Paroxysmal	13	P, Q, Ds	Previous HB ablation
7	42/M	Incessant	5	D, V, Ds	Cardiomyopathy
8	42/F	Paroxysmal	42	D, V, P, Ds	—
9	26/M	Paroxysmal	26	D, V, Ds, Q, A	—
10	37/F	Paroxysmal	23	D, V, P, Q, A	ASD (repaired)
11	42/F	Paroxysmal	10	D, V, P, Ds	Aortic stenosis
12	26/F	Paroxysmal	1	D, V, P, A	—
13	26/F	Paroxysmal	6	D, V, Fl	—
14	32/M	Paroxysmal	15	D, V, P, Q, A	ASD (repaired)
15	39/F	Incessant	1	D, V, P, Q	Sick sinus syndrome
16	16/M	Incessant	16	D, V	—
17	25/F	Incessant	9	D, V, Q, Ds	—
18	66/F	Paroxysmal	8	D, V, P, Q	AV junctional reentrant tachycardia

A = amiodarone; ASD = atrial septal defect; AV = atrioventricular; D = digoxin; Ds = disopyramide; F = female; Fl = flecainide; HB = His bundle; M = male; Met = metoprolol; P = propranolol; Q = quinidine; V = verapamil; — = not present.

8. Four patients had coexistent structural heart disease (Table 1). Two patients had additional disorders of cardiac rhythm, one patient having AV junctional reentrant tachycardia, and the other having sinoatrial node dysfunction. One patient (Case 6) had previously undergone catheter electroablation of the His bundle, but episodic atrial tachycardia continued to cause episodic presyncope. Two patients (Cases 10 and 14) had previously undergone repair of an atrial septal defect in the early days of cardiac surgery using the "well" technique. In both patients, the repair had been incomplete and an interatrial communication was still present.

Preoperative electrophysiologic studies. Details of our methods of investigating supraventricular arrhythmias have been published previously (1). In short, these studies were performed in the postabsorptive state after sedation with diazepam (10 mg orally). Quadripolar catheters (USCI, 6F) were placed in the high right atrium, right ventricular apex and coronary sinus. A tripolar catheter (USCI, 6F) was placed across the tricuspid valve ring to record the His bundle signal. Localization of the earliest atrial activation during tachycardia was performed using a modified Brockenbrough catheter (Elecath, 7F). Atrial tachycardia was distinguished from tachycardia due to AV junctional reentry or that utilizing concealed accessory ventriculoatrial connections by methods described previously (1).

Intraoperative electrophysiologic study. A button electrode was sutured to the epicardium of the right ventricular outflow tract, and a clip electrode was placed on the left

atrial appendage. These electrodes were used for pacing and recording. Induction of tachycardia was attempted before instituting cardiopulmonary bypass because we believe that atrial cannulation tends to interfere with induction of atrial tachycardia. If atrial pacing or extrastimuli failed to induce atrial tachycardia, induction was attempted after infusion of isoproterenol (5 μ g boluses intravenously); if this failed, atropine was administered (0.5 mg given intravenously). Epicardial mapping was performed using a hand-held bipolar probe with interelectrode distance of 1 mm. Electrograms were recorded from 20 preselected atrial sites. Activation time was calculated with reference to the electrode fixed to the left atrial appendage. Detailed mapping was then performed, recording 5 to 10 electrograms from the region of earliest atrial activation. Immediate postoperative mapping was not performed because the arrhythmia could not be induced in any patient.

Surgical technique. Details of our surgical techniques have been reported previously (11). Excision of atrial tissue was performed during cardioplegic arrest. Autologous pericardium was used for closure of atrial defects. Cryoablation was not used. In one patient (Case 17), tachycardia appeared to arise from the low right atrium near the AV node; it was not possible to excise this area, so His bundle section was performed. One patient (Case 18) had also suffered from AV junctional reentrant tachycardia, and perinodal dissection was performed in addition to an isolation procedure for the atrial tachycardia. Details of the method of perinodal dissection have been reported previously (12).

Table 2. Preoperative and Intraoperative Electrophysiologic Studies in 18 Patients

Case No.	Preoperative Study					Intraoperative Study	
	Method of Induction	Earliest Site	Atrial CL (ms)	Atrial ERP (ms)	Effect of Extrastimuli	Method of Induction	Earliest Site
1	AP	Near SAN	390	180	*	AP	Near SAN
2	Present	HAM-RA	340	210	†	Present	Roof atrial septum
3	Present	RA App	420 to 500	ND	†	Present	RA-App
4	Present	HL-RA	520	170	†	Atropine	Near SAN
5	Present	HAL-RA	420	180	†	Isop	Near SAN
6	NI	—	—	ND	†	NI	—
7	Present	MAM-RA	390	ND	*	Present	RA-App
8	NI	—	—	160	†	NI	—
9	AP	HA-RA	260 to 320	ND	*	AP	RA-App
10	AP	HA-RA	380	ND	*	AP	Near SAN and RA-App
11	AP	HM-RA	520	180	*	AP	LA-App
12	NI	—	—	180	†	NI	—
13	NI	—	—	210	†	NI	—
14	AP and isop	HAL-RA	460	210	*	AP and isop	Near old atriotomy scar
15	Present	HA-RA	370 to 490	120	†	Present	RA-App
16	Present	HA-RA	440 to 470	170	†	Present	RA-App
17	AP	LM-RA	350	250	*	Present	Low interatrial septum
18	AP	HAL-RA	430	220	*	AP	Near SAN

*Atrial tachycardia could be reproducibly induced or terminated with atrial extrastimuli or pacing; †atrial tachycardia could not be reproducibly induced or terminated with atrial extrastimuli or pacing. AP = atrial pacing or extrastimuli; App = appendage; CL = cycle length; ERP = effective refractory period; HA = high anterior; HAL = high anterolateral; HAM = high anteromedial; HL = high lateral; HM = high medial; isop = isoproterenol; LA = left atrium; LM = low medial; MAM = mid-anteromedial; ND = not determined; NI = not induced; Present = arrhythmia present spontaneously; RA = right atrial; SAN = sinoatrial node.

Histopathologic examination. Atrial tissue was available for examination in 16 patients. Tissue was not excised in Case 17 in which the His bundle section was performed, nor in Case 18 in which an isolation procedure was performed. The sinoatrial node and adjacent areas were included in the resection in six patients. All specimens were received fresh and were sectioned into slices of 3 mm, fixed in Mellonig's buffered formalin (pH 7.4) and embedded in paraffin blocks. Sections 4 μm thick were stained with hematoxylin-eosin and examined by light microscopy.

Postoperative electrophysiologic studies. All patients except one (Case 8) underwent electrophysiologic testing 1 week after surgery. In these studies, epicardial wires implanted at surgery were used for recording and pacing. Repeat electrophysiologic testing was performed 6 months after the time of surgery in 10 patients. Late electrophysiologic testing was not performed in eight patients for the following reasons: five patients declined, two had suffered recurrences of tachycardia and one had not yet been followed up for 6 months. The method of testing was the same as that of preoperative testing.

Analysis. Unless otherwise stated, all results are expressed as mean values ± SD. Results were analyzed on an "intention to treat" basis (that is, all patients were submitted to surgery with the intention of ablating the arrhythmic focus). Analysis of the probability of recurrence was performed using the methods of Kaplan and Meier (13).

Results

Preoperative electrophysiologic study (Table 2). Atrial tachycardia occurred spontaneously during the study or was induced in 14 (78%) of the 18 patients. The method of tachycardia induction and the site of earliest atrial activation are shown in Table 2. In 17 patients, atrial activation during tachycardia proceeded in a craniocaudal direction. In one patient (Case 17), the atria were activated in a caudocranial direction. In this patient, it was unlikely that the arrhythmia was due to AV junctional reentry because dual AV node pathways were not present and AV block occurred spontaneously during tachycardia. Tachycardia could not be induced in four patients; in these patients, the P wave configuration was identical to that during sinus rhythm, and it was assumed that the origin of the tachycardia was near the sinoatrial node. Sinus tachycardia and atrial tachycardia with similar P wave configurations were distinguished by the paroxysmal nature of the latter (in the absence of precipitating events) or, if the arrhythmia was incessant, by the exclusion of factors known to cause sinus tachycardia, such as thyrotoxicosis, drugs, anxiety, fever, pregnancy or cardiac failure.

Intraoperative electrophysiologic study (Table 2). Tachycardia could not be induced in the same four patients in whom it could not be induced in the preoperative study. In these patients, the position of the sinoatrial node was deter-

Table 3. Surgical Procedures and Follow-Up Data for 18 Patients

Case No.	Procedure	SAN Excised, Isolated	PPM	1 Week EPS		6 Month EPS		Clinical Follow-up Data		
				AT Induced	CL (ms) ER	AT Induced	CL (ms) ER	Recurrence	Time to Recurrence (weeks)	Length of Follow-up (months)
1	E and P	—	—	—	640	—	710	—		93
2	E	—	—	—	680	+	740	+	4	106
3	E and P	—	—	—	680	—	730	—		99
4	E and P	—	—	—	935	NP	NP	+	4	95
5	E and P	+	+	—	PPM	—	PPM	—		77
6	E and P	+	PI	—	PPM	—	PPM	—		22
7	E and P	—	—	—	660	—	750	—		86
8	E and P	+	+	NP	600	NP	NP	—		53
9	E and P	—	—	—	750	NP	NP	—		64
10	E and P	+	—	—	840	NP	NP	—		61
11	E and P	—	—	—	650	NP	NP	—		62
12	E and P	+	—	—	720	NP	NP	+	2	41
13	E and P	+	—	—	880	—	920	+	52	21
14	E and P	—	—	—	1020	—	880	+	60	28
15	E and P	—	—	—	840	—	800	—		15
16	E and P	—	—	—	800	—	780	—		6
17	HBS	—	+	—	PPM	NP	NP	—		72
18	Iso upper RA AVJRT diss	+	+	—	1000	NP	NP	—		2

AT = atrial tachycardia; AVJRT diss = dissection for atrioventricular junctional reentrant tachycardia (see text); E = excision of portion of atrium; EPS = electrophysiologic study; ER = escape rhythm; HBS = section of His bundle; Iso upper RA = isolation of upper right atrium; NP = not performed; P = application of pericardial patch; PI = permanent pacemaker inserted previously; PPM = insertion of permanent pacemaker; + = yes; - = no; other abbreviations as in Table 2.

mined by mapping. The induction of anesthesia terminated atrial tachycardia in one patient, but it was possible to induce the arrhythmia after administration of atropine (0.5 mg intravenously). The site of earliest atrial activation during tachycardia in the remaining 14 patients is shown in Table 2.

Histopathologic examination. The mean area of atrial tissue resected was $10 \pm 6 \text{ cm}^2$. Definite abnormalities were noted in four patients (25%). In two patients (Cases 10 and 14), extensive patches of myocardial fibrosis separated viable bundles of myofibrils. Both these patients had previously undergone attempted repair of an atrial septal defect. In two patients (Cases 7 and 11), there was evidence of myofiber hypertrophy and endocardial fibrosis. In Case 7, these changes were thought to be secondary to a cardiomyopathy and in Case 11 to valvular heart disease. In three patients (Cases 2, 5 and 8), moderate to marked fatty infiltration separated the myocardium into thin strands and bundles. Because fatty infiltration is also observed in patients without arrhythmias, the significance of this finding is uncertain. In the remaining nine patients (56%), no abnormalities or minimal nonspecific changes were present. Definite histologic abnormalities were found in all four patients with structural heart disease, but not in any patient whose heart was clinically normal. In all four patients with definite histologic abnormalities, atrial tachycardia could be repro-

ducibly induced and terminated with atrial extrastimuli, suggesting that in these patients, the arrhythmia was caused by reentry or triggered activity rather than by enhanced automaticity.

Early postoperative electrophysiologic study (Table 3). Tachycardia could not be induced in any patient at 1 week after surgery. The cycle length of the spontaneous rhythm recorded at this time is shown in Table 3.

Late postoperative electrophysiologic study (Table 3). "Late" electrophysiologic testing was performed 6 months after surgery in 10 patients. Atrial tachycardia was induced in one patient (Case 2). In this patient, the arrhythmia had recurred spontaneously 4 weeks after surgery. Of the five patients who had documented clinical recurrence of arrhythmia, four underwent late testing, and in only one patient was the arrhythmia induced. It should be noted, however, that the arrhythmia had not been inducible in these patients at the preoperative electrophysiologic study. The cycle length of spontaneous rhythm at the time of testing is shown in Table 3.

Complications. A permanent pacemaker was implanted in four patients. A permanent pacemaker had been implanted in one patient (Case 6) before surgery (see earlier). In one patient (Case 17), the proximity of the arrhythmic focus to the AV node made resection impossible and, thus, His bundle section was performed and a permanent pace-

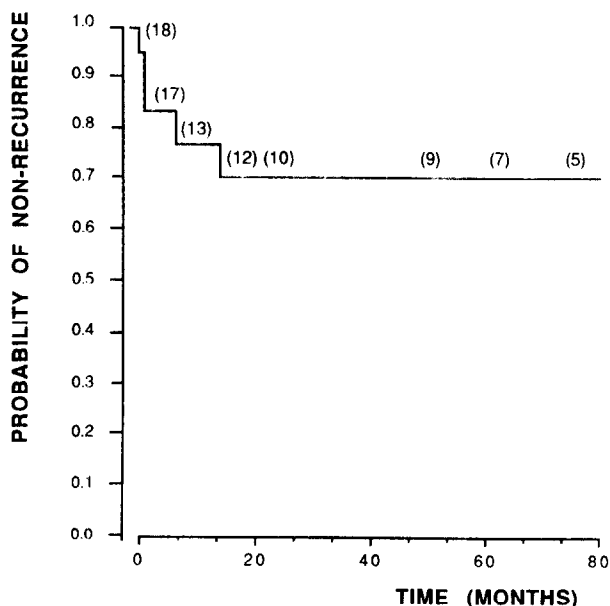


Figure 1. Kaplan-Meier analysis of the probability of remaining free of recurrence of atrial tachycardia after surgery. The mean follow-up period was 56 ± 34 months (median 61). Numerals in parentheses refer to the size of the study group (arrhythmia free) at various times after surgery.

maker implanted. In one patient (Case 8), excision of the sinoatrial node resulted in a slow escape rhythm that was judged likely to produce symptoms, and a permanent pacemaker was implanted at the time of surgery. This patient later developed an adequate junctional escape rhythm. One patient (Case 18) appeared to have an adequate escape rhythm in the early postoperative period, but symptomatic bradycardia developed 8 weeks after surgery and a permanent pacemaker was implanted. Atrioventricular node function was normal in this patient at electrophysiologic study 1 week after surgery. One patient (Case 5) developed frequent symptomatic atrial and ventricular ectopic beats after sinoatrial node resection, and a permanent pacemaker programmed to a high rate was later implanted in an effort to control the ectopic beats. One patient developed a lower respiratory tract infection in the early postoperative period.

Clinical follow-up (Table 3). The mean clinical follow-up period for our patients was 56 ± 34 months. During this period, atrial tachycardia recurred in five patients (28%). The time to recurrence is shown in Table 3, and Kaplan-Meier analysis of recurrence is shown in Figure 1. Repeat surgery was undertaken in two patients. In one patient, His bundle section was performed and a permanent pacemaker implanted; this patient remains asymptomatic. In the second patient, isolation of the right atrium was attempted; however, this was unsuccessful and His bundle section was performed. After this procedure, it was discovered that this patient had been taking unprescribed doses of thyroxine.

The patient has been asymptomatic since discontinuing this practice. The patient denied taking excess thyroxine and had a normal plasma thyroid hormone concentration before the first surgical procedure.

Discussion

We report the largest series yet published of adult patients undergoing surgery for atrial tachycardia refractory to medical therapy. The results indicate that atrial tachycardia can be cured in the majority of patients, but a small proportion will require permanent cardiac pacing if the arrhythmogenic area is near the sinoatrial node. Although surgery for atrial tachycardia appears to be moderately successful, the results are not as good as those achieved in patients with supraventricular tachycardia associated with accessory AV connections, in whom the success rate approaches 100% (14).

Factors affecting surgical success. These factors are not easy to identify from the relatively small series published to date. It is self-evident that the ability to induce the arrhythmia at electrophysiologic study is necessary to accurately locate the arrhythmic focus at the time of surgery. This cannot be done if the arrhythmia cannot be induced when required. Although it is commonly held that atrial tachycardia "is frequently suppressed by general anesthesia" (14), this has not been our experience. In all patients in whom the arrhythmia was incessant or could be induced preoperatively, it remained present or could be induced intraoperatively. One factor that may have contributed to the ability to induce tachycardia intraoperatively was our practice of attempting to induce the arrhythmia before the insertion of the atrial cannulas used for cardiopulmonary bypass. We believe that the insertion of these cannulas may prevent induction by traumatizing the arrhythmogenic area. In addition, we avoided the use of atropine or scopolamine as premedication because these drugs frequently induce sinus tachycardia, which may be difficult to distinguish from atrial tachycardia.

Patient selection may also influence surgical outcome. In all patients in our series in whom the tachycardia originated from one of the atrial appendages, the outcome of surgery was uniformly successful. The reasons for this finding are uncertain, but obviously in these patients, the sinoatrial and AV nodes were unlikely to be damaged and the appendage could be resected with little deformation of the atrial anatomy.

In four of the five patients in whom tachycardia recurred, the tachycardia could not be induced or terminated with extrastimuli, thus suggesting that the recurrence was due to enhanced automaticity rather than to reentry or triggered activity. These cases may be associated with a more diffuse atrial abnormality, although there was no histologic evidence of this. In two patients, the arrhythmia did not recur until >1

year after surgery, thus suggesting that the abnormality may be progressive. Before surgery, these patients experienced daily episodes of the arrhythmia, and it seems likely that these "recurrences" represent tachycardia from a "new" focus.

Requirement for cardiac pacing. A permanent pacemaker was implanted in five patients (28%). In Case 6, it had been implanted before attempted surgical cure, and in Case 17, it was implanted because resection of the arrhythmia had been impossible and His bundle section had been performed. In Case 8, the pacemaker appears to have been implanted unnecessarily because the patient later developed an adequate escape rhythm, and in Case 5, a pacemaker was inserted in an attempt to control symptomatic ectopic beats. Thus, excluding the patient in whom a permanent pacemaker was implanted before surgery, permanent pacing was required for symptomatic bradycardia in only one of the six patients in whom the sinoatrial node was excised or isolated.

Histologic findings. Although few investigators have described their histologic findings, in most reported cases abnormalities have been noted. Wyndham et al. (4) described mononuclear cell infiltration of the epicardium and increased myocardial connective tissue in a single patient, and Josephson et al. (5) reported a proliferation of mesenchymal cells in their patient. Iwa et al. (7) described proliferation of small atypical cells in a patient with left atrial tachycardia, and Frank et al. (8) found islets of fatty cells in a single patient. In contrast, in our study, definite abnormalities were found in only 25% of the patients.

Conclusions. Surgical therapy of focal atrial tachycardia is a safe and moderately successful method of treatment. The success rate is not as high as for other supraventricular arrhythmias such as those associated with accessory AV connections, but surgery is preferable to His bundle destruction and results will undoubtedly improve as more is learned about the pathophysiology of this arrhythmia.

References

1. Ross DL, Denniss AR, Uther JB. Electrophysiologic study in supraventricular arrhythmias. *Cardiovasc Clin* 1985;15:187-213.
2. Gillette PC, Garson A. Electrophysiologic and pharmacologic characteristics of automatic ectopic atrial tachycardia. *Circulation* 1977;56:571-5.
3. Coumel PH, Aigueperse J, Perrault MA, Fantoni A, Slama R, Bouvrain Y. Reperage et tentative d'exeresse chirurgicale d'un foyer ectopique auriculaire gauche avec tachycardie rebelle: evolution favorable. *Ann Cardiol Angiol* 1973;22:189-99.
4. Wyndham CR, Arnsdorf MF, Levitsky S, et al. Successful surgical excision of focal paroxysmal atrial tachycardia: observations in vivo and in vitro. *Circulation* 1980;62:1365-72.
5. Josephson ME, Spear JF, Harken AH, Horowitz LN, Dorio RJ. Surgical excision of automatic atrial tachycardia: anatomic and electrophysiologic correlates. *Am Heart J* 1982;104:1076-85.
6. Anderson KP, Stinson EB, Mason JW. Surgical exclusion of paroxysmal atrial tachycardia. *Am J Cardiol* 1982;49:869-74.
7. Iwa T, Ichihashi T, Hashizume Y, Ishida K, Okada R. Successful surgical treatment of left atrial tachycardia. *Am Heart J* 1985;109:160-2.
8. Frank G, Baumgart D, Klein H, Luhmer I, Kallfelz HC, Borst HG. Successful surgical treatment of focal atrial tachycardia: a case report and review of the literature. *Thorac Cardiovasc Surg* 1986;34:398-402.
9. Seals AA, Lawrie GM, Magro S, et al. Surgical treatment of right atrial focal tachycardia in adults. *J Am Coll Cardiol* 1988;11:1111-7.
10. Gillette PC, Wampler DG, Garson A, Zinner A, Ott D, Cooley D. Treatment of atrial automatic tachycardia by ablation procedures. *J Am Coll Cardiol* 1985;6:405-9.
11. Johnson DC, Nunn GR, Richards DA, Uther JB, Ross DL. Surgical therapy for supraventricular tachycardia, a potentially curable disorder. *J Thorac Cardiovasc Surg* 1987;93:913-8.
12. Ross DL, Johnson DC, Denniss AR, Cooper MJ, Richards DA, Uther JB. Curative surgery for atrioventricular junctional reentrant tachycardia. *J Am Coll Cardiol* 1985;6:1383-92.
13. Kaplan EL, Meier P. Nonparametric estimation from incomplete observations. *J Am Stat Assoc* 1958;53:457-81.
14. Cox JL. The status of surgery for cardiac arrhythmias. *Circulation* 1985;71:413-7.