

Acute Beta-Blockade Reduces the Extent and Severity of Myocardial Perfusion Defects With Dipyridamole Tc-99m Sestamibi SPECT Imaging

Raymond Taillefer, MD, FRCP,* Alan W. Ahlberg, MA,† Yasmin Masood, MD,†
C. Michael White, PHARM.D,‡ Isabella Lamargese, MD, FRCP,* Jeffrey F. Mather, MS,‡
Carol C. McGill, LPN,† Gary V. Heller, MD, PhD, FACC†

Montréal, Canada; and Hartford and Farmington, Connecticut

OBJECTIVES	The goal of this study was to examine the effect of acute beta-blockade on dipyridamole Tc-99m sestamibi myocardial perfusion imaging (DMPI).
BACKGROUND	Studies suggest that antianginal drugs may reduce the presence and severity of myocardial perfusion defects with dipyridamole stress. However, there are no data regarding specific drugs.
METHODS	Patients with catheterization-proven coronary artery disease (CAD) were enrolled in this prospective, double-blind, placebo-controlled study and randomly assigned to DMPI after placebo, low-dose metoprolol (up to 10 mg), and high-dose metoprolol (up to 20 mg). Patients underwent one Tc-99m sestamibi study at rest on a separate day. The interval between DMPI studies was ≤ 14 days. Images were interpreted by three observers blinded to clinical data using a 17-segment, five-point model. For each image, a summed stress score (SSS), summed rest score (SRS), and summed difference score (SDS) were calculated ($SDS = SSS - SRS$). Images with an $SSS < 4$ were considered normal.
RESULTS	Twenty-one patients completed all four Tc-99m sestamibi studies. The sensitivity of DMPI for detection of CAD was 85.7% with placebo versus 71.4% with low- and high-dose metoprolol. In comparison with placebo, the SSS was significantly lower ($p < 0.05$) with low- and high-dose metoprolol (12.0 ± 10.1 vs. 8.7 ± 9.0 and 9.3 ± 10.6 , respectively). The SDS also was significantly lower (8.4 ± 8.8 with placebo vs. 5.0 ± 6.7 [$p < 0.001$] and 5.4 ± 7.9 [$p < 0.01$] with low- and high-dose metoprolol, respectively).
CONCLUSIONS	The presence and severity of CAD may be underestimated in patients receiving beta-blocker therapy undergoing dipyridamole stress myocardial perfusion imaging. (J Am Coll Cardiol 2003;42:1475-83) © 2003 by the American College of Cardiology Foundation

The value of stress myocardial perfusion imaging (MPI) in the assessment of patients with known or suspected coronary artery disease (CAD) is well documented. Although the diagnostic accuracy of exercise and pharmacologic MPI is high and similar, various factors may negatively impact sensitivity. The inability to achieve 85% of maximal pre-

See page 1484

dicted heart rate with exercise can lead to an underestimation of the presence and extent of CAD as detected by MPI (1-3). Concomitant antianginal drug therapy also has been shown to affect MPI results with exercise (4-8) and dobutamine (9). Due to competitive inhibition, caffeine-containing products negatively affect vasodilator MPI (10,11).

Patients receiving antianginal drugs may be referred for vasodilator stress under the assumption that these medications have no impact on MPI results (12-14). However,

Sharir et al. (15) evaluated patients with dipyridamole MPI and found a significant reduction in the presence, extent, and severity of defects when patients did not discontinue antianginal medications before testing. One class of cardiac drugs, beta-blockers, are commonly used in the treatment of angina. Although beta-blockers have been shown to reduce detection of CAD with MPI using exercise or dobutamine (4-9), there are no data regarding beta-blockers with vasodilator MPI. The purpose of this study was to examine the effects of acute beta-blocker therapy upon vasodilator MPI in patients with CAD.

METHODS

Study design. This was a prospective double-blind, placebo-controlled, randomized study in which patients with CAD were submitted on separate days to dipyridamole Tc-99m sestamibi single-photon emission computed tomography (SPECT) imaging without supplemental exercise (dipyridamole myocardial perfusion imaging [DMPI]) after randomized acute administration of placebo, low-dose metoprolol, and high-dose metoprolol. Myocardial perfusion studies were performed at two centers: the Department of Nuclear Medicine of the Centre Hospitalier de l'Université de Montréal and the Nuclear Cardiology Laboratory, Hartford Hospital, Hartford, Connecticut.

From the *Department of Nuclear Medicine, Centre Hospitalier de l'Université de Montréal (pavillon Hotel-Dieu), Montréal, Canada; †The Henry Low Heart Center, Division of Cardiology, Hartford Hospital, Hartford, Connecticut; and ‡University of Connecticut School of Medicine, Farmington, Connecticut.

Manuscript received December 10, 2002; revised manuscript received May 1, 2003, accepted May 9, 2003.

Abbreviations and Acronyms

CAD	= coronary artery disease
DMPI	= dipyridamole myocardial perfusion imaging
LAD	= left anterior descending coronary artery
MPI	= myocardial perfusion imaging
RCA	= right coronary artery
SDS	= summed difference score
SPECT	= single-photon emission computed tomography
SRS	= summed rest score
SSS	= summed stress score

Patient population. Twenty-five patients with stable CAD were prospectively evaluated. Inclusion criteria were evidence of obstructive CAD, defined as a 70% stenosis in at least one major coronary artery, on coronary angiography, without subsequent revascularization, within 12 weeks of enrollment. All patients provided written informed consent as approved by both institutional review boards.

Exclusion criteria were left main disease, hypertrophic cardiomyopathy or aortic stenosis, myocardial infarction <30 days, unstable angina <7 days, uncontrolled systemic hypertension (systolic blood pressure >200 mm Hg or diastolic blood pressure >110 mm Hg), severe valvular disease, percutaneous coronary intervention <3 months, coronary artery bypass graft surgery <6 months, history of malignant ventricular arrhythmia, history of reversible airways disease, or history of allergy to dipyridamole or aminophylline.

Study protocol. Beta-blockers and calcium antagonists were withheld ≥ 48 h and ≥ 24 h, respectively, before each appointment after approval by the patient's primary physician. Patients were advised to refrain from consumption of products containing caffeine for ≥ 24 h before each appointment. For the first appointment, patients underwent acute metoprolol titration without DMPI. The purpose of this preliminary trial was to: 1) determine the dosage of metoprolol required for the subsequent low- and high-dose beta-blocker conditions before DMPI, and 2) permit randomization of the treatment conditions.

For the next three appointments, each patient was sub-

mitted to standard DMPI after three different treatment conditions, assigned in random fashion: 1) placebo (normal saline solution), 2) acute administration of low-dose metoprolol, and 3) acute administration of high-dose metoprolol. The time interval between each DMPI study was ≥ 7 but ≤ 14 days. On a separate day and before the DMPI studies, patients underwent Tc-99m sestamibi SPECT imaging at rest.

Metoprolol titration protocol. A total of 4 mg of metoprolol was infused over 4 min followed by a 5-min wait before administration of the next 4-mg dose to a total cumulative dose of 12 mg. If a titration end point was not achieved after a total cumulative dose of 12 mg, 2 mg was infused over 2 min followed by a 5-min wait before administration of the next 2-mg dose, to a total cumulative dose of 20 mg. Titration end points were: 1) reduction in baseline heart rate $\geq 25\%$; 2) reduction in baseline heart rate $\geq 15\%$ after a total cumulative metoprolol dose of 20 mg. The metoprolol infusion was terminated if patients achieved either of the following exclusion end points: 1) reduction of systolic blood pressure <90 mm Hg, 2) heart rate <45 beats/min, 3) significant side effects including bronchospasm or congestive heart failure, or 4) atrioventricular block greater than second degree-Mobitz I. Symptoms and three-lead electrocardiogram (ECG) were continuously monitored, and heart rate and blood pressure were measured and recorded before the next dose of metoprolol.

Metoprolol and placebo administration before dipyridamole stress. Administration of metoprolol for the low- and high-dose conditions followed the same titration regimen described above. For each patient, the exact dosage of metoprolol achieved with the preliminary trial was administered for the high-dose condition. The dosage of metoprolol for the low-dose condition was 50% of that achieved with the preliminary trial. For the placebo condition, normal saline (4 ml) was infused over 4 min followed by a 5-min wait before administration of the next 4-ml dose for a total cumulative dose of 12 ml. A total of 10 min after the last dose of placebo, low-dose metoprolol, or high-dose metoprolol patients underwent DMPI.

Table 1. Effects of Acute Low-Dose and High-Dose Metoprolol Administration on Hemodynamic Parameters at Rest

	Baseline	Post-Administration	p Value
Low-dose metoprolol (9.0 \pm 1.9 mg)			
HR (beats/min)	72 \pm 12	61 \pm 8	<0.001
SBP (mm Hg)	142 \pm 15	135 \pm 13	0.019
DBP (mm Hg)	73 \pm 11	71 \pm 9	0.058
Rate-pressure product (HR \times SBP)	10,340 \pm 2,350	8,350 \pm 1,410	<0.001
High-dose metoprolol (18.0 \pm 3.9 mg)*			
HR (beats/min)	72 \pm 11	59 \pm 7	<0.001
SBP (mm Hg)	139 \pm 19	131 \pm 17	0.001
DBP (mm Hg)	73 \pm 11	70 \pm 11	0.014
Rate-pressure product (HR \times SBP)	9,980 \pm 1,920	7,840 \pm 1,460	<0.001

*There were no significant differences in any of the hemodynamic parameters at baseline or after beta-blocker administration between the low-dose and high-dose metoprolol treatment conditions.

DBP = diastolic blood pressure; HR = heart rate; SBP = systolic blood pressure.

Table 2. Hemodynamic Responses During Dipyridamole Stress Study With Placebo, Low-Dose Metoprolol, and High-Dose Metoprolol

	Placebo	Low-Dose Metoprolol	High-Dose Metoprolol
Pre-stress			
HR (beats/min)	72 ± 11	61 ± 7*	59 ± 7*
SBP (mm Hg)	142 ± 15	136 ± 12	135 ± 20
DBP (mm Hg)	74 ± 11	71 ± 9	71 ± 12
Rate-pressure product (HR × SBP)	10,260 ± 2,150	8,410 ± 1,350*	8,080 ± 1,600*
Peak stress			
HR (beats/min)	76 ± 12§	72 ± 9	72 ± 9
SBP (mm Hg)	135 ± 15†	130 ± 17	131 ± 17
DBP (mm Hg)	70 ± 9†	68 ± 11	67 ± 16
Rate-pressure product (HR × SBP)	10,470 ± 2,350	9,440 ± 1,960‡§	9,480 ± 1,950‡§

*p < 0.001 vs. placebo; †p < 0.05 vs. pre-stress ‡p < 0.05 vs. placebo; §p < 0.01 vs. pre-stress; ||p < 0.001 vs. pre-stress. Abbreviations as in Table 1.

Dipyridamole stress. Dipyridamole (0.56 mg/kg) was infused over 4 min. Patients' symptoms and three-lead ECG were continuously monitored. A dose of 30 to 45 mCi of Tc-99m sestamibi was injected 7 to 9 min after initiation of the infusion. The same dose was used for the rest study.

Tc-99m sestamibi imaging. Electrocardiogram-gated SPECT acquisition began 60 to 90 min after injection of radiopharmaceutical for rest, and DMPI and was performed using a dual-head SPECT camera (SMV/DST at HDM and ADAC/Vertex at HH) equipped with a 3/8" sodium iodide crystal and a low-energy, high-resolution collimator. Sixty-four projections (20 to 25 s/projection) were obtained over a 180-degree semicircular arc extending from right anterior oblique to left posterior oblique view. Filtered back projection was acquired using a Butterworth filter with a frequency cut-off of 0.66 cycles/pixel and an order of 5 for reconstruction of the transaxial slices to a thickness of 6.6 mm. No attenuation correction was used.

Image interpretation. All SPECT data was submitted to the same laboratory (Hotel-Dieu de Montréal, Montreal, Canada) for reconstruction and preparation of images for uniform display. All images were interpreted at the other laboratory (Hartford Hospital, Connecticut) by a consensus of three experienced observers without knowledge of the patient or treatment condition. For each patient, all three

stress images were interpreted separately in comparison with same rest image. For visual analysis, the left ventricle was divided into 17 segments using an apical, mid-, and basal short-axis slice as well as a mid-vertical long-axis view. Each segment was qualitatively scored using a 5-point scoring system (0 = normal, 1 = mild, 2 = moderate, 3 = severe reduction in photon activity, and 4 = absence of photon activity). For each image, a summed stress score (SSS) and summed rest score (SRS) was calculated by adding the scores for all 17 segments and within each vascular territory (left anterior descending artery [LAD] = seven segments, circumflex and right coronary artery [RCA] = five segments). Images and vascular territories with an SSS greater than the respective SRS were classified as reversible. For each image, a summed difference score (SDS) was calculated by subtracting the SRS from the SSS. Images and vascular territories with an SSS <4 and <2, respectively, were considered normal.

Statistical analysis. Data are expressed as mean ± one SD or as proportions. Hemodynamic variables were analyzed using repeated measures analysis of variance while the Friedman statistic was used to analyze SPECT variables. McNemars test for paired proportions was used to compare overall and regional (per vessel) sensitivity. Chi-square or the Fisher exact test was used to analyze clinical stress

Table 3. Clinical Effects of Low-Dose and High-Dose Metoprolol on Dipyridamole Stress Testing End Points

	Placebo	Low-Dose Metoprolol	High-Dose Metoprolol
Dipyridamole dose (mg)	48.1 ± 8.8	48.1 ± 8.8	48.1 ± 8.8
Reason for termination			
Completion of infusion	21 (100%)	21 (100%)	21 (100%)
Progressive angina	0	0	0
ST-T changes	0	0	0
Symptoms			
Any symptom	11/21 (52.4%)	10/21 (47.6%)	10/21 (47.6%)
Chest discomfort	7/21 (33.3%)	5/21 (23.8%)	6/21 (28.6%)
Nausea	1/21 (4.8%)	1/21 (4.8%)	2/21 (9.5%)
Headache	2/21 (9.5%)	2/21 (9.5%)	3/21 (14.3%)
Flushing	1/21 (4.8%)	4/21 (19.0%)	2/21 (9.5%)
Dyspnea	1/21 (4.8%)	1/21 (4.8%)	1/21 (4.8%)

There were no significant differences between placebo, low-dose, and high dose metoprolol conditions.

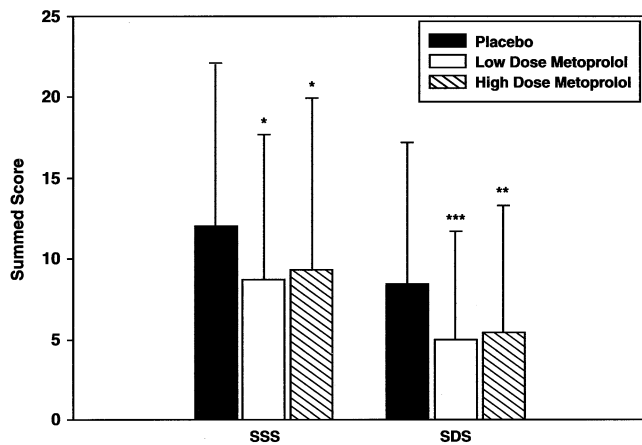


Figure 1. Impact of acute beta blocker therapy upon summed stress score (SSS) and summed difference score (SDS) with dipyridamole Tc-99m sestamibi single-photon emission computed tomography imaging. *p < 0.05; **p < 0.01; ***p < 0.001.

variables. Post-hoc comparisons were performed using either a paired *t* test or the Wilcoxon signed-rank test. Bonferroni adjustments were used as required. Significance was set at *p* < 0.05, and all analyses were two-tailed.

RESULTS

Patient population. Twenty-one patients (six female, mean age of 64 years [range 50 to 82]) completed all four MPI studies and constituted the study group. Four patients had previous myocardial infarction. On coronary angiography, five patients had single-vessel, eleven had double-vessel, and five had triple-vessel disease. A stenosis $\geq 70\%$ was found in 14 LAD, 15 circumflex, and 13 RCAs.

Metoprolol titration. For each patient, the dosage of metoprolol administered for the low-dose condition was exactly 50% of that determined for the high-dose condition (9.0 ± 1.9 mg and 18.0 ± 3.9 mg, respectively). Administration of low- and high-dose metoprolol significantly reduced heart rate, blood pressure, and double product (Table 1).

Dipyridamole stress. In comparison with placebo, pre-stress heart rate and double product were significantly lower with low- and high-dose metoprolol (Table 2). Infusion of dipyridamole resulted in an increase in heart rate and a decrease in blood pressure with each condition. Despite a more profound increase in heart rate with either dose of metoprolol, double product at peak dipyridamole stress remained significantly lower with each dose of metoprolol. There were no differences in the incidence of symptoms between each condition (Table 3).

Dipyridamole Tc-99m sestamibi imaging. Dipyridamole myocardial perfusion imaging with placebo was normal in three patients (14.3%), showed fixed defects in one (4.8%), and reversible defects in 17 (80.9%). Results of DMPI with low- and high-dose metoprolol were similar: normal in six patients (28.6%), fixed defects in three (14.3%), and reversible defects in 12 (57.1%). Sixteen patients (76.2%) had

Table 4. Dipyridamole Tc-99m Sestamibi Imaging Results

	Placebo	Low-Dose Metoprolol	High-Dose Metoprolol
Number of segments scored ≥ 1 on DMPI (defect extent)	6.4 ± 3.7	$4.6 \pm 3.5^\dagger$	$4.9 \pm 4.5^*$
Number of segments scored ≥ 2 on DMPI (defect severity)	3.5 ± 3.4	$2.4 \pm 2.9^*$	2.7 ± 3.3
Number of reversible segments on DMPI	5.6 ± 4.1	$3.3 \pm 3.7^\ddagger$	$3.8 \pm 4.8^*$

**p* < 0.05 vs. placebo; †*p* < 0.01 vs. placebo; ‡*p* < 0.001 vs. placebo. DMPI = dipyridamole myocardial perfusion imaging.

similar DMPI results with placebo, low-dose, and high-dose of metoprolol: normal in three patients (14.2%), fixed defects in one (4.8%), and reversible defects in 12 (57.1%). However, the SSS and SDS were significantly lower with each dose of metoprolol (Fig. 1). In addition, the number of segments with a score ≥ 1 or ≥ 2 on DMPI (reflecting the size and severity of defects, respectively) as well as the number of reversible segments were significantly lower with metoprolol (Table 4).

The mean reduction in the SSS with low- and high-dose metoprolol was 30.7% and 27.1%, respectively. Of the 18 patients with abnormal perfusion on DMPI with placebo, 11 (61.1%) had a greater than 25% reduction in the SSS with either or both doses of metoprolol. Conversely, only two patients (9.5%) had a greater than 25% increase in the SSS with either dose of metoprolol. None of the patients with normal perfusion on DMPI with placebo had abnormal perfusion with metoprolol. Similar findings were observed with the SDS (Fig. 2). There were five patients with reversible defects with placebo, which was negated with metoprolol (normal perfusion in three and fixed defects in two). Three of these patients had multivessel disease. The overall sensitivity of DMPI for detection of CAD was lower with metoprolol than placebo (71.4% [15/21 patients] vs. 85.7% [18/21 patients], respectively), although this did not achieve statistical significance (*p* = 0.25). However, a significantly lower sensitivity was found on a per vessel basis (52.4% with low- and high-dose metoprolol [22/42 diseased coronary vessels] vs. 69.1% with placebo [29/42 diseased coronary vessels], *p* = 0.039).

Images from three patients are illustrated (Figs. 3 to 5). In Figure 3, DMPI with placebo demonstrated a large and severe perfusion abnormality in the anterolateral, inferolateral, and inferobasal regions. With metoprolol, the size and severity of the perfusion abnormality on DMPI was reduced by approximately 50% in visual assessment. This patient had a 90% distal LAD stenosis, 70% proximal circumflex stenosis, and an occluded first marginal. Figure 4 shows DMPI images from a patient with an 85% RCA stenosis and a 90% proximal LAD stenosis. With placebo, DMPI showed a medium completely reversible anteroseptal, anteroapical, and distal inferoapical perfusion abnormality. With each metoprolol dose, the anterior perfusion abnormality was reduced by

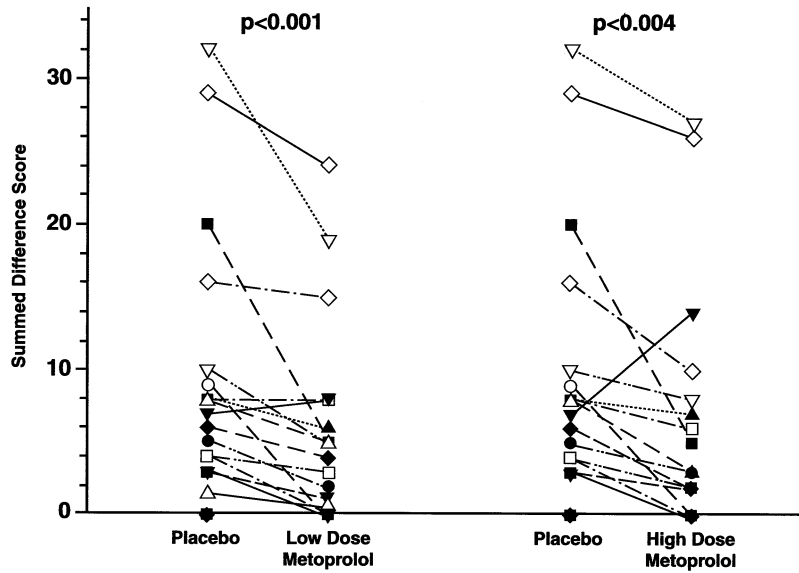


Figure 2. Individual data points comparing the summed difference score (SDS) on dipyridamole Tc-99m sestamibi single-photon emission computed tomography imaging after administration placebo and low-dose metoprolol and placebo and high-dose metoprolol. In both cases, the differences in the SDS between placebo and each dose of metoprolol were statistically significant.

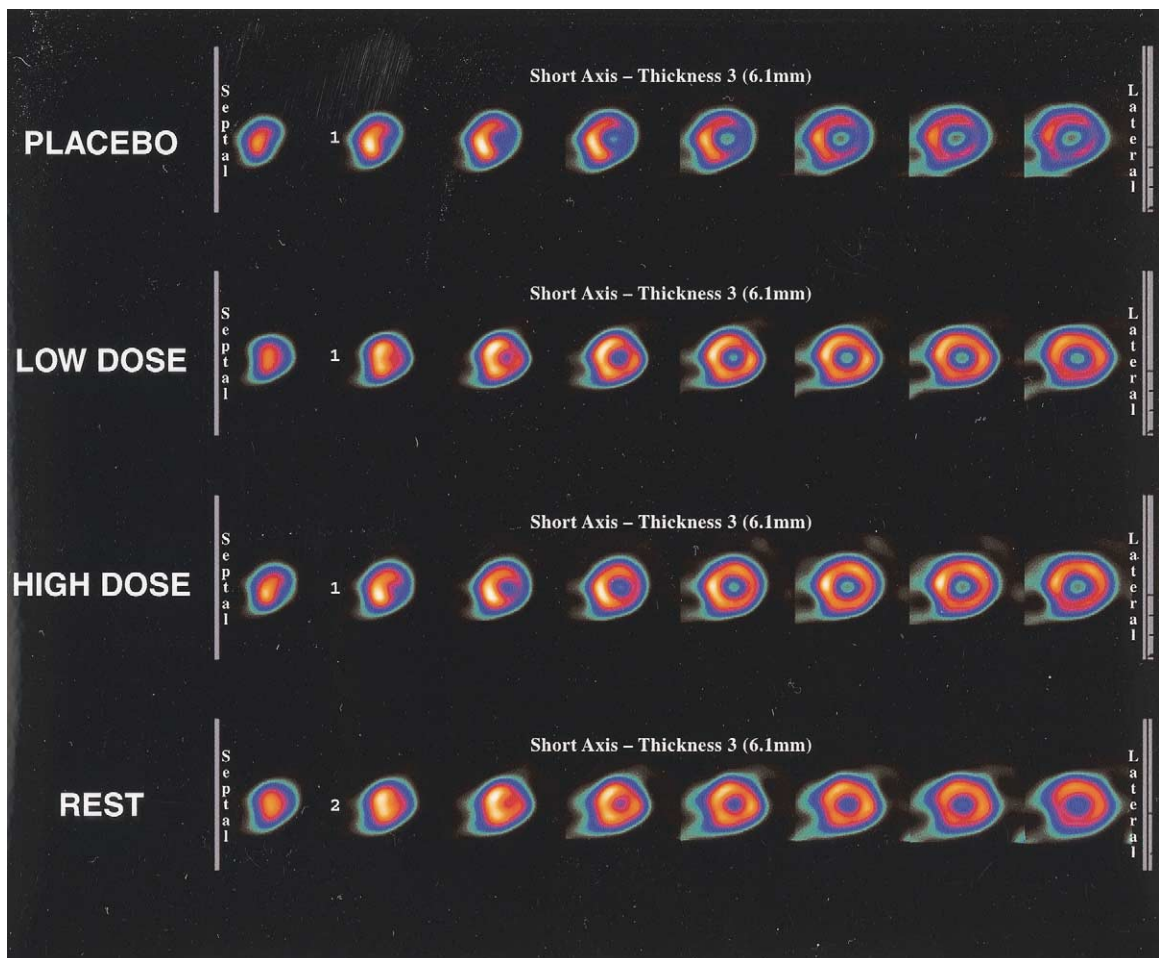


Figure 3. Multiple short-axis slices during dipyridamole Tc-99m sestamibi single-photon emission computed tomography (SPECT) imaging in a patient with coronary artery disease after administration of placebo, low-dose metoprolol, and high-dose metoprolol, as well as Tc-99m sestamibi SPECT imaging at rest. A large reversible anterolateral and inferolateral perfusion abnormality is shown with placebo, with at least 50% reduction in size and severity with either dose of metoprolol.

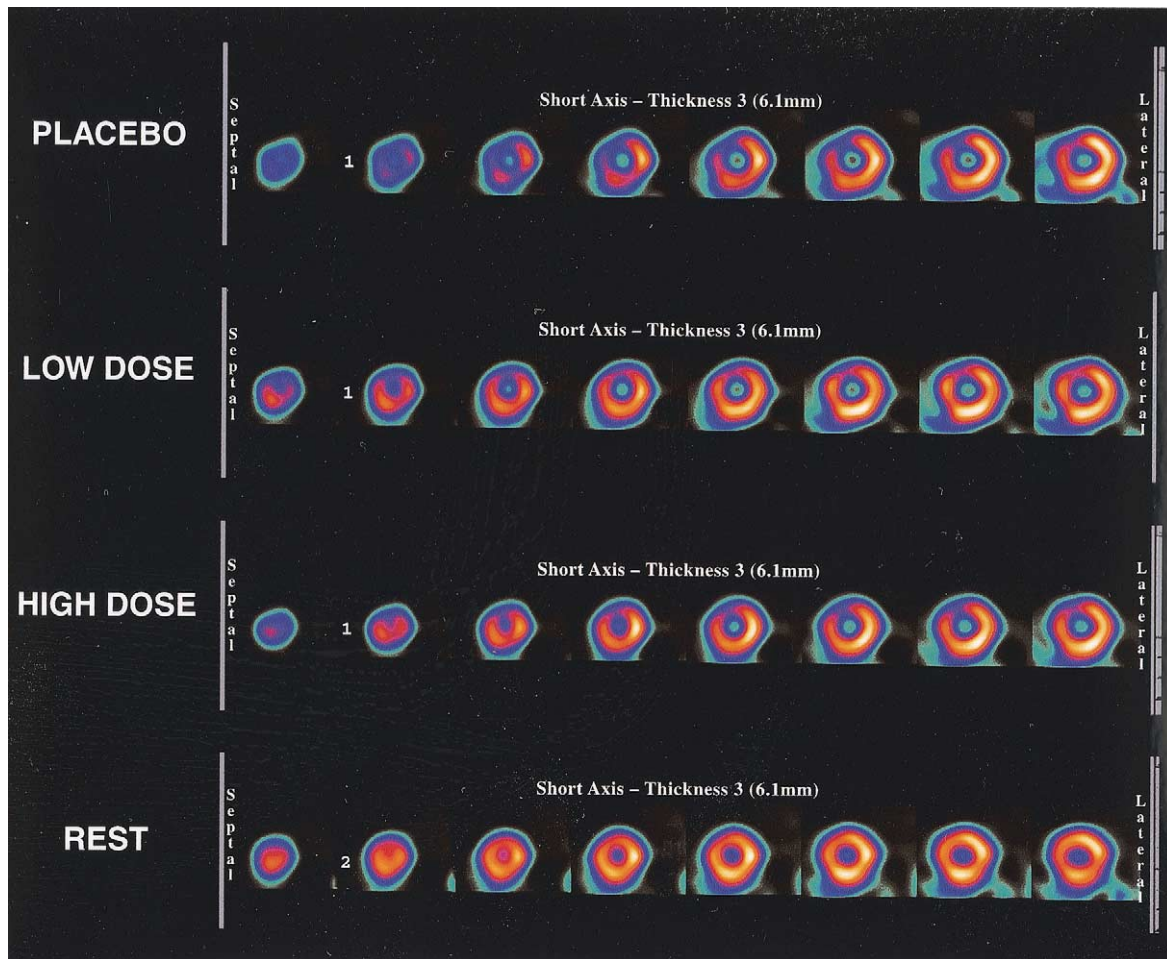


Figure 4. Multiple short-axis slices during dipyridamole Tc-99m sestamibi single-photon emission computed tomography (SPECT) imaging in a patient with coronary artery disease after administration of placebo, low-dose metoprolol, and high-dose metoprolol, as well as Tc-99m sestamibi SPECT imaging at rest. A medium-sized anteroseptal, anterolateral, and distal inferolateral perfusion abnormality is shown with placebo, with approximately 60% reduction in size and severity noted with both doses of metoprolol.

approximately 60% in visual assessment. Figure 5 shows images from a patient with multivessel disease. As with the other two cases, the extent and severity of perfusion abnormalities were reduced by at least 50% with both metoprolol doses.

DISCUSSION

It is well recognized that several classes of cardiac drugs reduce sensitivity as well as defect size and severity with exercise MPI (4-8). It has been assumed that concomitant cardiac drugs do not affect MPI results with vasodilator stress, although recent data from Sharir et al. (15) suggests a negative impact upon sensitivity as well as defect size and severity. Our study was performed to evaluate the impact of isolated beta-blocker therapy upon DMPI. Results demonstrate a significant reduction in the size, severity, and reversibility of defects after acute metoprolol administration. These findings have important clinical implications in the diagnostic and risk stratification assessment of patients receiving beta-blocker therapy referred for vasodilator MPI.

Impact of antianginal drugs upon exercise MPI. Experimental studies have shown that beta adrenergic blockade reduces exercise-induced ischemia through alteration of regional myocardial blood flow (16). In the clinical setting, the sensitivity of exercise MPI is reduced in patients unable to achieve a maximum predicted heart rate (1) or if receiving antianginal drugs (5,8). Concurrent beta-blocker therapy has also been shown to significantly reduce rate-pressure product and the severity of defects with exercise MPI (17-19). For these reasons, patients referred for exercise MPI for the diagnosis of CAD are generally instructed to discontinue antianginal drugs, particularly beta-blockers, for at least 48 h before testing (18).

Impact of antianginal drugs upon vasodilator MPI. Data regarding the impact of antianginal drugs upon detection of CAD with vasodilator stress are contradictory. With echocardiography, all three classes of antianginal drugs have been shown to negatively impact detection of regional wall motion abnormalities during dipyridamole stress (20). Similarly, calcium channel blockers have been shown to nega-

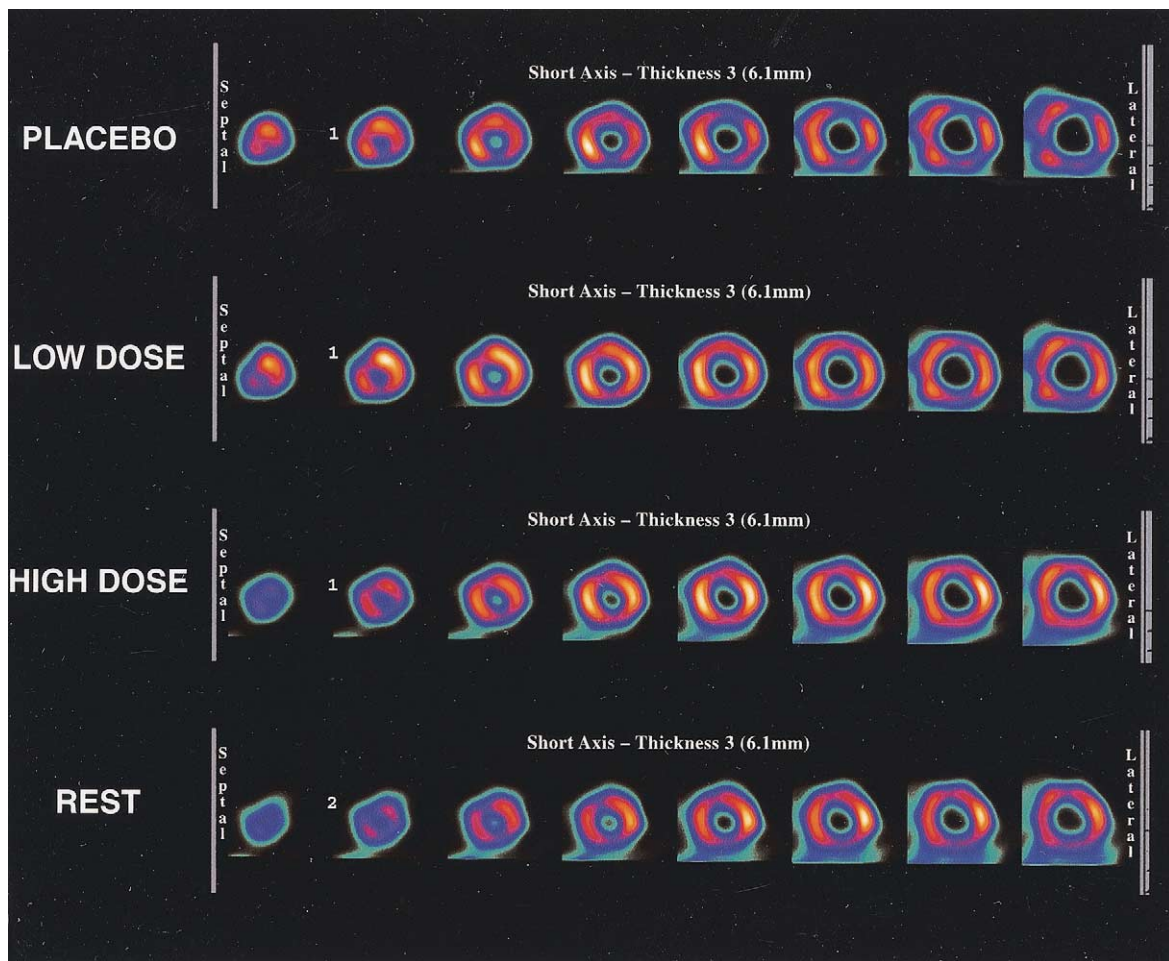


Figure 5. Multiple short-axis slices during dipyridamole Tc-99m sestamibi single-photon emission computed tomography (SPECT) imaging in a patient with coronary artery disease after administration of placebo, low-dose metoprolol, and high-dose metoprolol, as well as Tc-99m sestamibi SPECT imaging at rest. Multiple perfusion abnormalities are present with placebo with marked reduction in size and severity with both doses of metoprolol.

tively affect detection of CAD with DMPI (21). Conversely, two studies have suggested that antianginal drugs have no impact on detection of CAD with vasodilator stress and, if any, an increase in ischemia (22,23). Those studies were retrospective in design and involved two separate patient groups. Sharir et al. (15) compared data from the same patients and found a significant reduction in sensitivity and defect size, severity, and reversibility when DMPI was performed without discontinuation of antianginal drugs. In that study, the majority of patients were being treated with calcium antagonists and/or nitrates, and 77% were receiving multiple drugs at the time of testing. Our results suggest a similar effect with DMPI in the presence of acute beta-blocker therapy alone, even in low doses.

Potential mechanisms by which beta-blocker therapy affects vasodilator MPI. Dipyridamole increases endogenous adenosine concentrations by inhibiting adenosine deaminase and preventing adenosine uptake into erythrocytes and vascular endothelial cells (24,25). Adenosine binds to A₂ receptors in the smaller coronary vessels, which are coupled to stimulatory G-proteins. G-proteins increase

adenylate cyclase activity, which creates cAMP (26). Increasing cAMP within coronary arterioles causes vasodilation by enhancing the rate of inactivation of myosin light chain kinase, the enzyme responsible for triggering the actin-myosin interaction that causes contraction (27). Vasodilation in a nonstenotic coronary vessel increases the pressure gradient enhancing blood flow (28-32). Conversely, in a coronary vessel with significant stenosis, the ability to dilate is compromised, and blood flow is shunted away leading to a reduction in the driving pressure required for collateral flow (33). This is the basis for the myocardial steal phenomenon, whereby a greater percentage of blood flow is shunted away from ischemic zones after dipyridamole use (34,35).

Beta-2 receptors are coupled to the same types of stimulatory G-proteins as the A₂ receptors for adenosine (26). It is possible that beta-2 receptor blockade within the coronary vasculature attenuates the cAMP response from A₂ receptor stimulation. If this is the mechanism, it suggests that a similar interaction may occur between adenosine and beta-blockade. In addition, beta-blockers increase the time of

diastole, which increases time for myocardial tissue perfusion, potentially augmenting perfusion in ischemic zones (25).

As described by Sharir et al. (15), calcium antagonists and nitrates also exert a negative impact on accurate identification of the presence and severity of CAD with MPI (15). In this case, it may be a direct vasodilatory mechanism responsible for attenuation of the myocardial steal phenomenon.

Study limitations. The number of patients evaluated was limited. Although a trend towards a lower overall sensitivity was noted, this did not reach statistical significance. However, a significant reduction in sensitivity on a per vessel basis was found with each dose of metoprolol. This study used an acute intravenous beta-blocker model rather than chronic oral therapy. While it can be implied that the results would be the same, this cannot be stated conclusively. In the study of Sharir et al. (15), 31% of patients were receiving chronic beta-blockers with similar results. These data suggest that beta-blockers should be withheld in patients in which the purpose of the study is diagnosis and/or risk stratification of CAD. Such discontinuation of medications should be performed with caution, however, as a rebound effect in symptoms has been reported. If the purpose of the study is to assess the effectiveness of medical therapy, beta-blockers should be continued. This study examined the effects of beta-blockade on DMPI, and not adenosine. While the vasodilator effects are similar, adenosine may have a greater hyperemic effect (36). Sundereswaran et al. (37) evaluated two separate patient groups, one taking antianginal drugs and the other not taking antianginal drugs at the time of adenosine MPI, and found a lower sensitivity in the former group. To our knowledge, there are no data on the impact of acute beta-blockade on adenosine MPI.

Conclusions. In patients with CAD, acute administration of intravenous beta-blocker significantly reduces the extent, severity, and reversibility of defects with DMPI.

Acknowledgments

The authors express gratitude to the following individuals who participated in this study: Dr. Maha Mikhail, Dr. Carol Gemayel, Scott Harrison, CNMT, Andre Gagnon, CNMT, Carole Benjamin, CNMT, Sylvie Lajeunesse, CNMT, and Elizabeth Doucette for manuscript preparation.

Reprint requests and correspondence: Dr. Raymond Taillefer, Nuclear Medicine, Centre Hospitalier de l'Université de Montréal (pavillon Hotel-Dieu), Montréal, Canada. E-mail: rtaillefer@hotmail.com.

REFERENCES

1. Iskandrian AS, Heo J, Kong B, Lyons E. Effect of exercise level on the ability of thallium-201 tomographic imaging in detecting coronary artery disease: analysis of 461 patients. *J Am Coll Cardiol* 1989;14:1477-86.
2. Heller GV, Ahmed I, Tilkemeier PL, Barbour MM, Garber CE. Influence of exercise intensity on the presence, distribution, and size of thallium-201 defects. *Am Heart J* 1992;123:909-16.
3. Heller GV, Ahmed I, Tilkemeier PL, Barbour MM, Garber CE. Comparison of chest pain, electrocardiographic changes and thallium-201 scintigraphy during varying exercise intensities in men with stable angina pectoris. *Am J Cardiol* 1991;68:569-74.
4. Frisch C, DeSanctis R, Doge H, Reeves T, Weinberg S. Guidelines for exercise testing: a report of the American College of Cardiology/American Heart Association Task Force on Assessment of Cardiovascular Procedures (Subcommittee on Exercise Testing). *J Am Coll Cardiol* 1986;8:725-38.
5. Hockings B, Saltissi S, Croft DN, Webb-Peploe MM. Effect of beta adrenergic blockade on thallium-201 myocardial perfusion imaging. *Br Heart J* 1983;49:83-9.
6. Martin GJ, Henkin RE, Scanlon PJ. Beta blockers and the sensitivity of the thallium treadmill test. *Chest* 1987;92:486-7.
7. Burns RJ, Kruzyk GC, Armitage DL, Druck MN. Effect of anti-anginal medications on the prognostic value of exercise thallium scintigraphy. *Can J Cardiol* 1989;5:29-32.
8. Mahmarian JJ, Fenimore NL, Marks GF, et al. Transdermal nitroglycerin patch therapy reduces the extent of exercise-induced myocardial ischemia: results of a double-blind, placebo-controlled trial using quantitative thallium-201 tomography. *J Am Coll Cardiol* 1994;24:25-32.
9. Shehata AR, Gillam L, Mascitelli V, et al. Impact of acute propranolol administration on dobutamine induced myocardial ischemia as evaluated by myocardial perfusion imaging and echocardiography. *Am J Cardiol* 1997;80:268-72.
10. Smits P, Corstens FHM, Aengevaeren WRM, Wackers FJT, Thien T. False-negative dipyridamole-thallium-201 myocardial imaging after caffeine infusion. *J Nucl Med* 1991;32:1538-41.
11. Heller GV, Dweik RB, Barbour MM, et al. Pretreatment with theophylline does not affect adenosine-induced thallium-201 myocardial imaging. *Am Heart J* 1993;126:1077-83.
12. Beller GA. Dipyridamole thallium-201 scintigraphy: an excellent alternative to exercise scintigraphy. *J Am Coll Cardiol* 1989;14:1642-4.
13. Bonaduce D, Muto P, Morgano G, et al. Effect of beta blockade on thallium-201 dipyridamole myocardial scintigraphy. *Acta Cardiol* 1984;39:399-408.
14. Picano E. Dipyridamole echocardiography test/historical background and physiologic basis. *Eur Heart J* 1989;10:365-76.
15. Sharir T, Rabinowitz B, Livschitz S, et al. Underestimation of extent and severity of coronary artery disease by dipyridamole stress thallium-201 single-photon emission computed tomographic myocardial perfusion imaging in patients taking antianginal drugs. *J Am Coll Cardiol* 1998;31:1540-6.
16. Matsuzaki M, Patritti J, Tajimi T, Miller M, Kemper WS, Ross J. Effects of β -blockade on regional myocardial flow and function during exercise. *Am J Physiol* 1984;247:H52-60.
17. Narahar K, Thompson C, Hazen J, Brizendine M, Mena I. The effect of beta blockade on single photon emission computed tomographic (SPECT) thallium-201 images in patients with coronary disease. *Am Heart J* 1989;117:1030-5.
18. Hockings B, Saltissi S. Effect of beta adrenergic blockade on thallium-201 myocardial perfusion imaging. *Br Heart J* 1983;49:83-9.
19. Muller-Suur R, Eiksson S, Strandber L. Comparison of adenosine and exercise stress test for quantitative perfusion imaging in patients on beta-blocker therapy. *Cardiology* 2001;95:112-8.
20. Lattanzi F, Picano E. Inhibition of dipyridamole-induced ischemia by antianginal therapy in humans. *Circulation* 1991;83:1256-62.
21. Kubota I, Ikeda K, Igarashi H. Inhibition of dipyridamole-induced myocardial ischemia by diltiazem in patients with coronary artery disease. *J Cardiovasc Pharmacol* 1987;9:363-7.
22. Santoro G, Sciagra R, Buonamici P, Consoli N, Mazzoni V. Head-to-head comparison of exercise stress testing, pharmacologic stress echocardiography and perfusion tomography as first-line examination for chest pain in patients without history of coronary artery disease. *J Nucl Cardiol* 1998;1:19-27.

23. Bridges A, Kennedy N, McNeill G. The effect of atenolol on dipyridamole 201Tl myocardial perfusion tomography in patients with coronary artery disease. *Nucl Med Commun* 1992;13:41-6.
24. Picano E. Dipyridamole echocardiography test: historical background and physiologic basis. *Eur Heart J* 1989;10:365-72.
25. United States Pharmacopeial Convention. USPDI-Volume I, Drug Information for the Health Professional. Englewood, CO: Micromedex, Inc., 2000.
26. Second messenger systems. In: Clark WG, Brater DC, Johnson AR, editors. *Goth's Medical Pharmacology*. St Louis, MO: Mosby Year Book, 1992:13-7.
27. Katzung BG, Chatterjee K. Vasodilators and the treatment of angina pectoris. In: Katzung BG, editor. *Basic & Clinical Pharmacology*. New York, NY: McGraw-Hill, 2001:181-99.
28. Young DF, Tsai FY. Flow characteristics in models of arterial stenosis. I. Steady flow. *J Biomech* 1973;6:395-410.
29. Young DF, Tsai FY. Flow characteristics in models of arterial stenosis: II. Unsteady flow. *J Biomech* 1973;6:547-59.
30. Gould KL, Lipscomb K, Calvert C. Compensatory changes of the distal coronary vascular bed during progressive coronary constriction. *Circulation* 1975;51:1085-94.
31. Gould KL, Lipscomb K. Effects of coronary stenoses on coronary flow reserve and resistance. *Am J Cardiol* 1974;34:48-55.
32. Flameng W, Wusten B, Schaper W. On the distribution of myocardial flow. II. Effects of arterial stenosis and vasodilation. *Basic Res Cardiol* 1974;69:435-46.
33. Becker LC. Conditions of vasodilator-induced coronary steal in experimental myocardial ischemia. *Circulation* 1978;57:1103-10.
34. Becker LC. Effect of nitroglycerin and dipyridamole on regional left ventricular blood flow during coronary artery occlusion. *J Clin Invest* 1976;58:1287-96.
35. Nakamura M, Nakayaki O, Nose Y, Fukuyama T, Kikuchi Y. Effects of nitroglycerin and dipyridamole on regional myocardial blood flow. *Basic Res Cardiol* 1978;73:482-96.
36. Wilson RF, Wyche K, Christensen BV, Zimmer S, Laxson DD. Effects of adenosine on human coronary arterial circulation. *Circulation* 1990;82:1595-606.
37. Sundereswaran L, He ZX, Verani MS, Mahmarian JJ. Influence of anti-anginal medications on the detection of coronary artery disease as assessed by single photon emission computed tomography combined with adenosine stress (abstr). *Circulation* 1996;94 Suppl I:I303.