

Preclinical Restenosis Models and Drug-Eluting Stents

Still Important, Still Much to Learn

Robert S. Schwartz, MD, FACC,*† Nicolas A. Chronos, MBBS,‡ Renu Virmani, MD§

Minneapolis, Minnesota; Atlanta, Georgia; and Bethesda, Maryland

Percutaneous coronary intervention continues to revolutionize the treatment of coronary atherosclerosis. Restenosis remains a significant problem but may at last be yielding to technologic advances. The examination of neointimal hyperplasia in injured animal artery models has helped in our understanding of angioplasty and stenting mechanisms, and as drug-eluting stent (DES) technologies have arrived, they too have been advanced through the study of animal models. These models are useful for predicting adverse clinical outcomes in patients with DESs because suboptimal animal model studies typically lead to problematic human trials. Similarly, stent thrombosis in animal models suggests stent thrombogenicity in human patients. Equivocal animal model results at six or nine months occasionally have been mirrored by excellent clinical outcomes in patients. The causes of such disparities are unclear but may result from differing methods, including less injury severity than originally described in the models. Ongoing research into animal models will reconcile apparent differences with clinical trials and advance our understanding of how to apply animal models to clinical stenting in the era of DESs. (J Am Coll Cardiol 2004;44:1373–85) © 2004 by the American College of Cardiology Foundation

Percutaneous coronary intervention continues to revolutionize atherosclerosis treatments. The understanding of angioplasty mechanisms came after these technologies were already in clinical use through the comparison animal model research with clinical pathologic specimens. An early understanding of balloon angioplasty suggested that atherosclerotic plaque was “compressed” or “stretched”—concepts that eventually yielded to a comprehensive understanding that both plaque and normal artery are severely fractured in many successful cases (good clinical percutaneous transluminal coronary angioplasty or stent result). Animal models assumed a central position in understanding coronary artery injury and healing. Neointimal formation results from vessel laceration, which is a response to injury during revascularization. Rare but valuable human necropsy material has confirmed animal model results showing that plaque that was fractured or lacerated by coronary angioplasty induced severe arterial injury and that restenosis resulted from this injury (1,2).

Much of what is known about restenosis and neointimal formation comes from intense study of animal injury models and comparison with human material, which usually is derived from autopsy. What is referred to as “restenosis” in normal animal arteries is not truly such; rather, it is neointima resulting from controlled injury that is induced in

normal vessels. Stenosis in these models results from thick and sometimes occlusive neointima forming after severe balloon or stent injury and also from vessel shrinkage (remodeling) due to scar formation. As injured normal animal arteries (rat, pig, mouse, dog, rabbit, primate) became the standard for understanding neointima and remodeling, they rapidly evolved into a new role, that of testing novel restenosis therapies (3,4). Many parallels emerged between human restenosis and its animal model counterparts. Each has strongly impacted our understanding of restenosis and its treatment.

ANIMAL RESTENOSIS MODELS: A BRIEF OVERVIEW

Rat carotid artery model. The rat carotid artery model was developed in the 1960s, and from it derived the foundations of vascular biology. Although first used to gain insight into human atherosclerosis, it was adapted to understand restenosis and to test restenosis therapy. This model became a standard for studying smooth muscle cell proliferation after endothelial denudation (5–11). One advantage of the model is that it provides one with the ability to study molecular biology (11–14).

This model assumed less importance after several early studies of angiotensin-converting enzyme inhibitors. These agents were very effective at inhibiting neointimal thickening, suggesting the importance of angiotensin II to neointimal growth (15,16). However, two subsequent clinical studies failed to show inhibitory effects (17–19). Angiotensin II has been the subject of ongoing interest (20–22), however, the failure of this model to predict negative clinical trial results has caused it to lose favor among investigators.

From the *Minneapolis Heart Institute and †Minnesota Cardiovascular Research Institute, Minneapolis, Minnesota; ‡American Cardiovascular Research Institute, Atlanta, Georgia; and §Armed Forces Institute of Pathology, Bethesda, Maryland. This manuscript summarizes three lectures presented at a “Meet the Experts” session held at the U.S. Food and Drug Administration entitled “Animal Restenosis Models, What Have We Learned?”

Manuscript received January 26, 2004; revised manuscript received March 28, 2004, accepted April 6, 2004.

Abbreviations and Acronyms

| | |
|--------|--|
| DES | = drug-eluting stent |
| IVUS | = intravascular ultrasonography |
| MLD | = minimum lumen diameter |
| PRESTO | = Prevention of REStenosis with Tranilast and its Outcomes trial |

Mouse arterial injury model. The mouse arterial injury as a restenosis model developed from the availability of the mouse genome and molecular methods to study events after arterial injury (23,24). The mouse has very small vessels; therefore, traditional injury methods by balloon or stent are not practical. Injury may instead be performed by rotating a small guidewire in the vessel (25–28) or electrical injury. Either of these methods causes endothelial loss and focal medial cell damage of 25% to 50%. The internal elastic lamina often is disrupted by these injury procedures. Variable neointimal thickening forms focally at injury sites in proportion to the amount of injury, and little thrombus occurs in this model.

Wound healing in the mouse model partially replicates other models because its features include mural thrombus resorption through inflammatory cell infiltration. A thin neointima (roughly 0.03 mm²) forms by three weeks. Because most or all arterial cells (in media and adventitia) are killed uniformly, these lesions heal from the borders. The power of molecular biology and genetics in these mouse models will permit substantial advances in understanding of the interactions among cell proliferation, cell migration, thrombus formation, and remodeling.

Hypercholesterolemic rabbit iliac model. The rabbit iliac restenosis model also has been studied extensively to test restenosis therapies and to understand cellular and molecular mechanisms (29–31). Blood cholesterol levels are typically >1,000 mg/dl and cause biochemical arterial injury, which is supplemented by mechanical injury.

These models add initial injury by air desiccation to hypercholesterolemic diets and finally balloon inflation to further injure the vessel. Unlike rat carotid arteries, macroscopic and hemodynamically significant stenoses similar to human restenosis develop reliably in the rabbit models. Histopathology in this model shows foam cells (macrophages that have ingested excessive lipid) and voluminous extracellular matrix. One criticism of this model is that foam cells are rare in human restenotic neointima. However, balloon angioplasty in this model does cause histopathologic injury comparable with that of human angioplasty, with medial dissection and plaque fracture.

Platelet deposition occurs rapidly at sites of a balloon-induced plaque fracture. Thus, antiplatelet agents were studied early in the history of this model as a potential therapy (32,33) and showed efficacy in reducing neointimal thickness. A wide variety of other agents have been studied in this model and are discussed later.

Porcine coronary injury model. The coronary arteries of domestic crossbred pigs respond similar to human coronary arteries after injury (34–36). A hypercholesterolemic diet produces lesions more severe in nature than standard laboratory diets (37,38). In this model, injury causes thick neointima within 28 days. The neointima is identical to human restenotic neointima. When a balloon-only injury is performed, a typical medial laceration occurs and is filled at 28 days by neointima. The amount of neointimal thickening is directly proportional to injury. This permits the creation of an injury-response regression relationship that quantitates the response to potential therapies (39–41).

Relevance to human coronary intervention. The porcine coronary models using injuries caused by either stenting or overstretching injury alone are now accepted standards by which potential restenosis therapies are studied, in large part because the stages of neointimal growth described in the porcine model follow those now known in humans. Empiric correlation with clinical trials suggests this may be true. Negative trials using the porcine model correspond well to negative clinical trials, suggesting that this model has good specificity. Fewer therapies have had positive results and, therefore, model sensitivity is less certain. Paclitaxel- and rapamycin-eluting stent studies suggest that positive results in these models are predictive of positive results in clinical trials. Interestingly, ionizing radiation to the coronary arteries in the pig model demonstrated neointimal stimulation rather than inhibition when gamma radiation was delivered externally (42). However, many studies of intravascular gamma and beta radiation show neointimal inhibition in pigs when examined at 28 days after therapy. Longer-term data are less conclusive and suggest little efficacy at longer time points.

Human coronary arteries develop radiation-induced coronary artery disease, although this is achieved typically with high doses of radiation that are given for many years. Several clinical studies in patients receiving vascular brachytherapy for in-stent restenosis show neointimal stimulation at the edges of radiated regions, where radiation doses are falling off. Moreover, several reports are emerging that suggest a “catch-up” phenomenon in patients receiving vascular brachytherapy. Six-month data in pigs showing lack of efficacy might have predicted this clinical finding; further long-term patient analysis is underway to determine potential relationships to the pig model. Continued observation over time will determine whether intravascular brachytherapy will stimulate accelerated coronary artery disease in patients.

Sensitivity for efficacy will be better assessed as additional strategies that are efficacious are developed. The data suggest that the porcine model is best for establishing safety, although efficacy remains less certain as discussed in detail below. Table 1 compares several human trials with preclinical results. This table includes references for brachytherapy (43–62), statins (63–67), angiotensin-converting enzyme inhibitors (18,19,21,68–72), anticoagulants (39,73–87),

Table 1. Comparison Between Clinical Trials and Porcine Preclinical Data

| | Porcine Model Safety/Efficacy | Human Data Safety/Efficacy |
|--|-------------------------------|----------------------------|
| Brachytherapy | +/+ (43-51) | +/+ (52-62) |
| Statins | -/- (63) | -/- (64-67) |
| Angiotensin-converting enzyme inhibitors | -/- (21,69-71) | -/- (18,19,68,72) |
| Anticoagulants | ±/± (39,73-81) | -/- (82-87) |
| Probucol | +/+ (88-94) | -/- (95-97) |
| Rapamycin/analogs | +/+ (98-100) | +/+ (101-105) |
| Paclitaxel | +/+ (106-110) | +/+ (111-115,177) |
| Calcium channel blockers | ±/- (116) | -/- (117-119) |
| c-myc antisense | +/+ (120,121) | -/- (122,123) |
| Dexamethasone | +/+ (124,125) | +/+ (126-128) |
| Heparin | (73,80,81,129,130) | (131-133) |

Data in parentheses are reference numbers.

probucol (88-97), rapamycin (98-105), paclitaxel (106-115), calcium channel blockade (116-119), antisense (120-123), dexamethasone (124-128), and heparin (74,80,81,129-133).

THE PROPORTIONALITY BETWEEN INJURY AND NEOINTIMAL THICKENING

Fundamentally, mature neointima is a repaired artery and thus is desirable. Problems arise in only a minority of cases

when exuberant neointima impinges on luminal blood flow. Early studies in the porcine coronary artery injury model suggested that deeper arterial injury results in greater neointimal thickening (35). This proportionality in the pig model was subsequently sought and validated in patients (Fig. 1). A practical outcome of this phenomenon was improved stent design, which sought to induce less arterial injury (134,135). Early wire stents could cause substantial injury if they were overexpanded; slotted tubular designs created fewer injuries and have prevailed in modern stent designs (36). Other stent concepts have attempted to limit injury even more but have been less successful, likely because a 90% stenosis when properly dilated undergoes 10-fold expansion. This expansion induces significant, unavoidable arterial injury by necessity and occurs both with angioplasty alone and with stenting. Drug-eluting stents (DESs) also induce such injury but rely on local drug effects to moderate the neointimal response.

Overstretch injury to pig coronary arteries holds important lessons for neointimal response to injury. Simple overstretch without stent implant usually causes medial fracture and laceration, with frequent dissections. A typical balloon:artery ratio is 1.2:1 or 1.3:1, which is visually estimated by the operator. These ratios generally create enough injury for satisfactory neointimal thickness without the risk of large dissections. Larger balloon:artery ratios yield a high likelihood of severe dissection with resulting thrombosis, coronary occlusion, and ensuing death from myocardial infarction and ventricular fibrillation. These balloon:artery ratios are finding use in DES efficacy studies.

When stents are implanted, dissections usually are controlled except at the stent margins. However, stent:artery

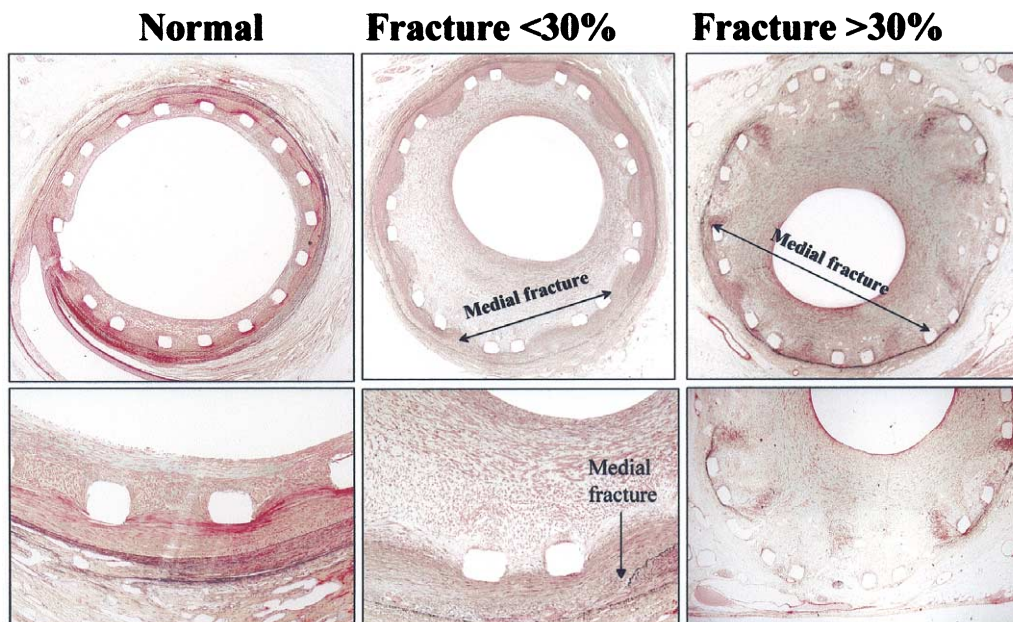


Figure 1. Stent-induced arterial injury in patients generates a proportional neointimal response. **Panels from left to right** indicate that as the internal elastic lamina becomes more severely disrupted by the stent and as the proportion of medial fracture transitions from <30% to >30% (**middle and right columns**), neointimal growth becomes progressively more severe.

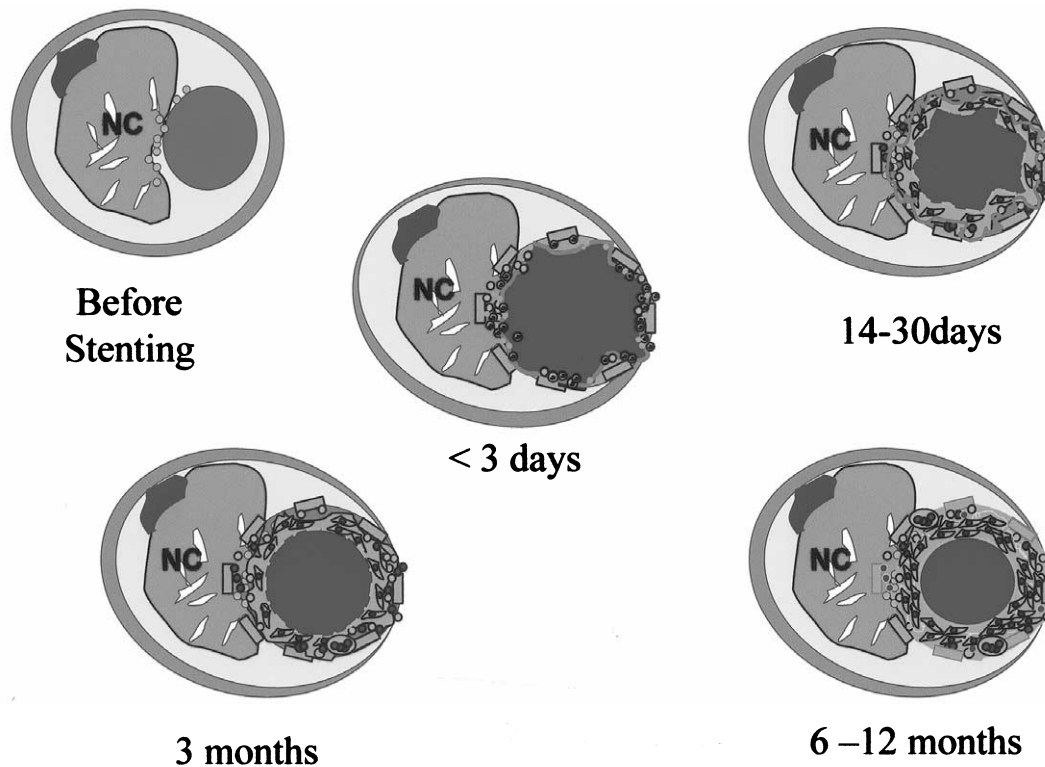


Figure 2. Diagram illustrating the time course of events leading to neointimal hyperplasia in atherosclerotic human coronary arteries. In the first stage, the atherosclerotic artery is depicted before stent placement. NC = non-cellular region of the plaque. Within the first three days after stent placement, platelets/fibrin and neutrophils accumulate at the stent site. At 14 to 30 days, chronic inflammation develops (macrophages, lymphocytes) and persistent fibrin is visible. Smooth muscle cells also are beginning to appear within the stent. At three months, chronic inflammation remains, and fibrin frequently persists. Proteoglycan and matrix deposition occurs. At 6 to 12 months, there often is persistent, chronic inflammation close to the struts, and endothelialization generally is complete. A neointima rich in smooth muscle cells, with a proteoglycan and collagen matrix, has developed. Adapted from Virmani et al. (136).

ratios of $>1.3:1$ often cause chronic vessel injury as the stent struts migrate through the vessel wall, including through the external elastic lamina and adventitia. Marked inflammation accompanies the stent struts when such oversizing is performed. This inflammation is highly undesirable because drug elution cannot overcome such severe and chronic injury, making stent/drug efficacy assessment not possible. It is for this reason that in preclinical DES testing, a more common practice is to use the balloon:artery ratio of 1.1:1, with the resulting data applied to safety analysis but not efficacy because neointimal generation at these low injury levels is minimal to mild. The relation of safety and efficacy studies with stented and overstenting alone remains to be determined. Figure 2 summarizes the time course of neointimal hyperplasia after stenting in patients. The important steps are summarized in the following text, as learned from animal models and translated to patients (136,137).

Thrombus and restenosis. Mural thrombus in porcine models is an early response to balloon dilation and stenting. It occurs less often in injured rat and dog arteries (138). A direct relationship between thrombus volume and neointimal volume is unproven but is thought likely.

Fibrin- and platelet-rich thrombus form on stent struts in porcine arteries within hours of implantation. It progressively resolves during the course of weeks, principally

through resorption by macrophages (139). Thrombus resolution and healing in porcine arteries closely reflect the healing in humans after stent implant. Near-total fibrin and thrombus resorption is a feature of complete arterial healing. Proven restenosis therapies such as vascular brachytherapy and DESs impede healing, and treated arteries often show unresolved fibrin thrombus (microscopic or sometimes gross) at times much later than found in untreated arteries.

Inflammation. Thrombus resolves by inflammatory cells (2,140,141). Macrophages secrete a variety of thrombolytic enzymes that digest thrombus as the macrophage tunnels into thrombus surrounding stent strut sites. Inflammation also may occur without thrombus, stimulated by local cytokines. Platelets and their contents appear in thrombus after degranulation and provide major chemokines for inflammation. These include P-selectin and integrins such as β_2 integrin Mac-1 (CD11b/CD18) (142). This integrin, located on the monocyte cell surface, is important because it is prominent in adhesion. Heterotopic platelet aggregation, a process where platelets aggregate on the monocyte surface and stimulate additional platelet activation, also plays an important role. The chemokines also are key for inflammation at vascular injury sites. Monocyte chemoattractant protein-1 attracts monocytes and activated T cells to vessel injury sites.

Inflammation is a potent and direct stimulus for neointimal thickening, in part through stimulating cell proliferation (143). Several animal models exhibit inflammation (monocytes/macrophages, lymphocytes, neutrophils) from stent coatings and drug-releasing polymers. These models suggest that biomedical polymers in DES applications cause inflammation to variable degree in proportion to the polymer mass on the stent. A major challenge in DES technology has been to find polymers that can control drug elution over the course of time yet incite minimal inflammation. Minor inflammation is presently acceptable, as evidenced in guidelines for testing DESs. The “perfect” polymer remains unknown, and all polymers in use today induce some degree of inflammation. It is for this reason that DESs tested in animal models should include quantitative inflammation measurements. A commonly used quantitative assessment of inflammation method is by Kornowski *et al.* (143).

Cell migration and proliferation. Cell migration and proliferation remain ill-defined in both animal models and in human neointimal hyperplasia. Although cell proliferation is implicated universally in neointimal hyperplasia, its quantitative role remains unclear. Early controversies about the role played by proliferation remain unresolved (144,145).

Both ionizing radiation and drugs effective against restenosis inhibit cell proliferation but have many additional cellular effects, including inhibiting migration, cell signaling, activation, and secretion, and may impair other important reparative features such as angiogenesis (146). These strategies are effective against neointima in multiple animal studies (147,148).

Therapies that are more specifically targeted at proliferation show less clear results. Gene therapy has been used in this strategy, for example, to express cell-cycle inhibitors (p21, p27, p53, and Rb) (149–151) or by halting cell cycle progression by inhibiting CDK2, cdc2, E2F, PCNA, myc, and myb (152–157). These gene-based strategies are marginally successful in animal models and have not been tested in clinical studies. Current DES success using rapamycin and paclitaxel rely on a multitude of cellular targets in addition to proliferation (158,159). The relative contribution of alternative effects is unknown but under investigation.

TIME COURSE OF CORONARY ARTERY HEALING AFTER STENTING

Coronary artery healing after stenting is reported for both the porcine model and in patients. Table 2 summarizes this information. Stent healing in pigs compared with patients suggests a time comparability of approximately 1:6 porcine: human, with pigs healing more rapidly. Reasons for the more rapid process in pigs are unclear but may include the young age of pigs, normal arteries compared with diseased human vessels, and other, as-yet-undetermined factors.

In the porcine model, coronary arteries typically are studied at 1, 3, 6, and 12 months. Although these times are

Table 2. Time Course Comparison of Events in Porcine and Human Coronary Stenting

| | Porcine Coronary Model | Human Stent Implantation |
|---|------------------------|--------------------------|
| Thrombus | 0–14 days | 0–30 days |
| Inflammation | 1–14 days | 0–30 days |
| Endothelialization and granulation tissue | 4–16 days | 14–90 days |
| Smooth muscle cells and matrix formation | 14–28 days | 2–6 months |

now standard, the reasons for time points after one month principally relate to safety because few changes occur in the pig model beyond this time, with the exception that neointima thins slightly later in the course of time. An unproven concept is that safety requires longer follow-up in pigs (presuming good results at one month) and that this theory might translate to long-term patient safety. The key to a safety evaluation in pigs is complete arterial healing, with thrombus resorption, minimal residual inflammation, and complete or near-complete endothelialization.

ANGIOGENESIS

Animal models exhibit angiogenesis at arterial lesion locations (Fig. 3). Marked disorganized angiogenesis occurs at stented sites in normal, non-diseased arteries for ill-defined reasons. Vascular hypoxia may be one cause and may result from the compression of adventitial vasa vasorum. Several angiogenic cytokines are upregulated in hypoxia, the most well known being hypoxia-inducible factor-1 alpha. Human atherosclerotic lesions are similarly angiogenic, especially in chronic total occlusions (146,160).

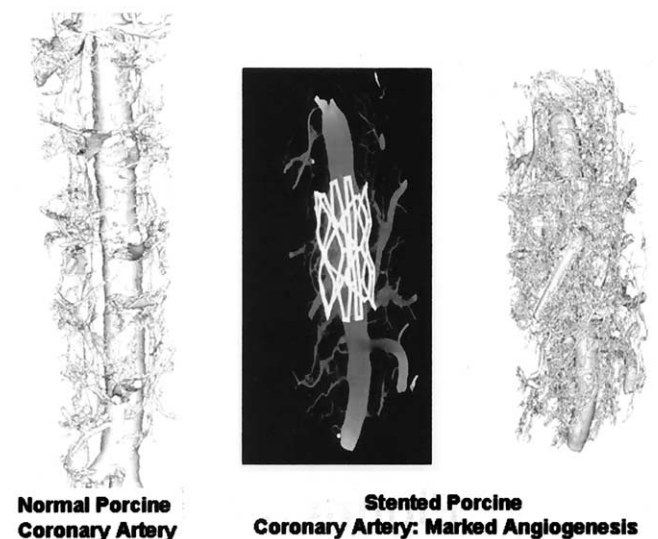


Figure 3. Microscopic computed tomography examination of normal (left) and stented (middle and right) porcine coronary arteries. Massive angiogenesis results in a highly vascular but disorganized array of vessels after the stenting of a normal porcine coronary artery. (Image courtesy Dr. Hyuck Moon Kwon.)

LESSONS FROM ANIMAL MODELS: SYSTEMIC RESTENOSIS THERAPIES

Most systemic restenosis treatments have failed and the literature contains many review articles on this topic (161–163). The Prevention of REStenosis with Tranilast and its Outcomes (PRESTO) trial, which tested oral tranilast to limit restenosis, is the most recent. Several animal studies showed neointimal hyperplasia was reduced in drug-treated animals and suggested oral tranilast efficacy. In one study, rabbits fed cholesterol showed inhibition of neointimal area by tranilast (300 mg/kg) (164). Another study in over-stretched porcine coronary arteries showed a 37% reduction in neointimal area normalized to fracture length (147). These and several other preclinical studies preceded the PRESTO trial (147,164–166).

Early small clinical trials showed tranilast could inhibit restenosis, prompting the large, randomized double-blind PRESTO trial of 11,484 patients (167). Primary end points were death, myocardial infarction, and ischemia-driven target vessel revascularization at nine months. Results showed a 15.8% event rate for placebo and 15.5% for tranilast ($p = \text{NS}$). The quantitative coronary angiography substudy comprised 2,018 patients and found that follow-up minimum lumen diameter (MLD) was 1.76 ± 0.77 mm in the placebo group compared with 1.78 ± 0.76 mm ($p = \text{NS}$). Intravascular ultrasonography showed no difference in plaque volume across tranilast doses. Thus, the PRESTO trial was analogous to events 10 years earlier in the Multicenter European Research Trial with Cilazapril after Angioplasty to Prevent Transluminal Coronary Obstruction and Restenosis (MERCATOR) and Multicenter American Research Trial with Cilazapril After Angioplasty to Prevent Coronary Obstruction and Restenosis (MARCATOR) trials (68). Each of these clinical trials was based on early preclinical data that were reported to show efficacy of the drug in question. Subsequent large, randomized clinical trials failed to show any efficacy.

The literature has many reports of preclinical systemic therapies that suggest efficacy of various pharmacologic agents. However, before beginning clinical trials, several important questions must be evaluated. Preclinical studies must use comparable drug doses and obtain comparable drug levels to those planned for clinical trials. Preclinical studies should use the same end points as used in clinical trials, which should include angiographic percent stenosis, absolute lumen MLD, late loss, or intravascular ultrasonography (IVUS)-based, lumen or neointimal parameters (3,145,168,169). An important reason for false-positive preclinical results may arise from histopathologic measurements differing from clinical indices. Such preclinical histopathologic measurements not available or not used in clinical trials include the intima:media ratio, percent neointimal reduction, or microscopic (but statistically significant) neointimal area inhibition. Animal model efficacy reports may yield different conclusions if angiographic or IVUS

parameters were standard. The best animal model metric to correlate with clinical data is an area of active investigation.

LESSONS FROM RESTENOSIS MODELS

Safety. Animal models play an instrumental role in developing and improving DES technology, a role that continues to evolve. Safety is the principal concern for any stent technology, and animal models appear useful in its assessment. The critical failure mode for stents is acute, subacute, or late closure because stent thrombosis nearly always has catastrophic implications. The porcine coronary stent model appears predictive for stent thrombosis. Several early studies of brachytherapy in pigs suggested that stent thrombosis might be a problem. Kaluza and Raizner (170) performed balloon and stent injury in healthy porcine coronary arteries, followed by intracoronary beta radiation. Five of 10 pigs given radiation died (50%) of stent thrombosis, whereas none died in the control (non-radiated) group. Stent thrombosis in the porcine coronary model is distinctly unusual, and subsequent patient studies of gamma brachytherapy showed subacute thromboses of up to 14% before the understanding that new stents should not be placed at brachytherapy sites (171–174). The relationship of porcine neointima after brachytherapy to comparable human studies is unclear. Several models show stimulation of neointimal hyperplasia by radiation, whereas clinical studies to date show no evidence of similar problems, at least in the near term.

Neointimal stimulation, rather than its suppression, is a second concern for stent safety, especially with DESs. Toxicity induced by high local drug concentration remains an ongoing concern and can show significant arterial changes. Although rabbit iliac arteries implanted with actinomycin-D showed good results (Fig. 4), the porcine coronary model appears to have predicted enhanced neointima in patients receiving actinomycin-D releasing stents by showing poor healing and neointimal stimulation (Fig. 5). These model studies showed incomplete stent healing, microthrombus, incomplete endothelialization, and late medial necrosis with marked neointimal thickening. The Actinomycin Eluting Stent Improves Outcomes by Reducing Neointimal Hyperplasia (ACTION) trial tested actinomycin-D elution in a randomized study. The trial was halted after 90 of 360 planned patients were enrolled and restenosis rates reached 28% in the highest dose group, suggesting neointimal stimulation (data shown at ESC 2002, Berlin, Germany). High restenosis rates also occurred in lower-dose groups; 25% and 17% for 2.5 μg and 10 μg actinomycin-D, respectively, versus 11% in controls.

Similarly predictive results from animal models were found using very high-dose taxane released from a suboptimal polymer, where the porcine model (Fig. 6) predicted worse clinical restenosis at 12 months. The Study to COmpare REstenosis rate between QueST and QuaDS-QP2 (SCORE) trial was stopped after enrolling 266 of 400

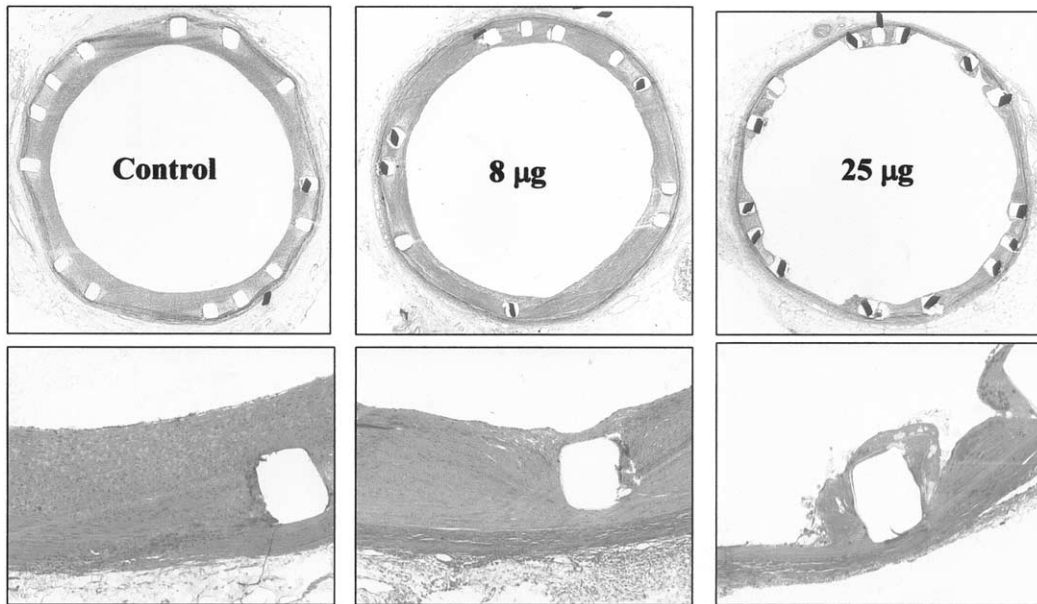


Figure 4. Actinomycin-D studies in rabbit iliac arteries. These images show excellent neointimal inhibition at 8 μg and 25 μg doses (middle and right columns), respectively, compared with control (left column). Lower rows are higher power views, showing that the 25- μg dose appears cytotoxic with poor healing present.

planned patients because of late events and increased 12-month restenosis rates (175).

These combined data suggest the porcine model can determine stent safety from both thrombosis and neointimal stimulation perspectives. Increased stent thrombosis in porcine coronary arteries should warn investigators about increased clinical thrombosis risk. Adverse vascular pathologies showing poor healing, vessel toxicity (for

example, medial necrosis or cell death), absent endothelialization, or neointimal stimulation should be of major concern.

DES efficacy. The accuracy of efficacy assessment for DESs in preclinical testing remains less clear than their safety. Because restenosis in the stent era is virtually all neointimal thickening, limiting neointima should translate directly from animal models to patients. Unfortunately, this

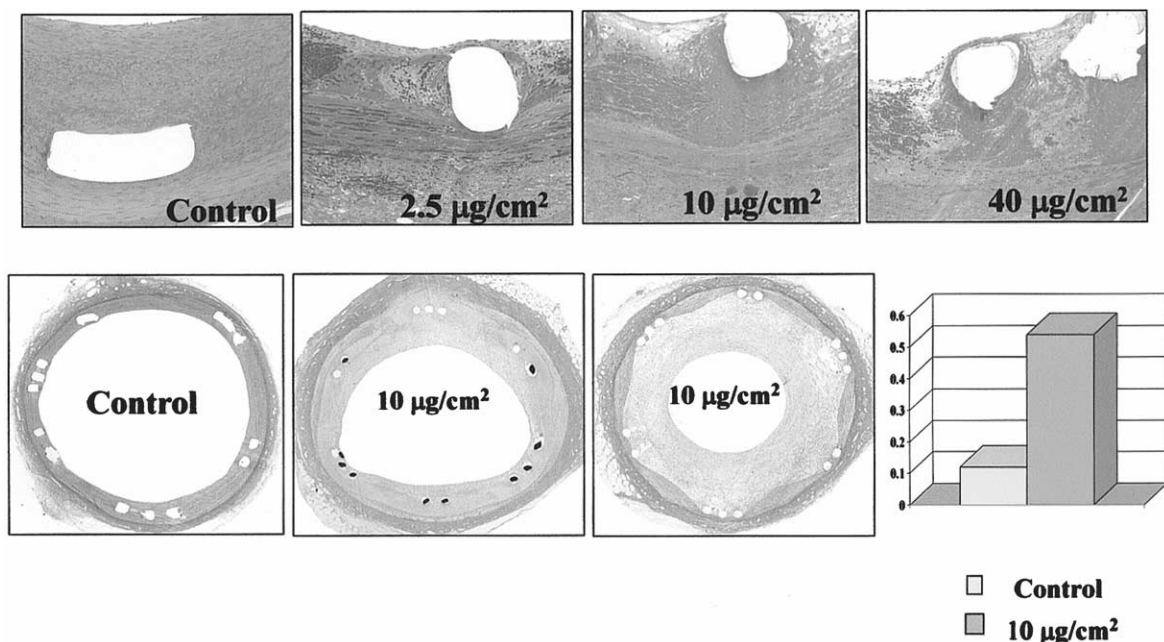


Figure 5. Porcine coronary arteries at 28 days (top) and 90 days (bottom) after actinomycin-D eluting stent placement. The 28-day data show substantial residual fibrin, inadequate vascular healing, but little mature neointima. At 90 days, there is a marked increase in neointimal thickening, greater than control, which occurred over time. The graph at lower right shows neointimal thickness measures for 90-day control and 10- μg datasets. The ACTION trial of actinomycin-D elution was stopped prematurely because of elevated major adverse clinical event rates due in part to abnormally high late loss.

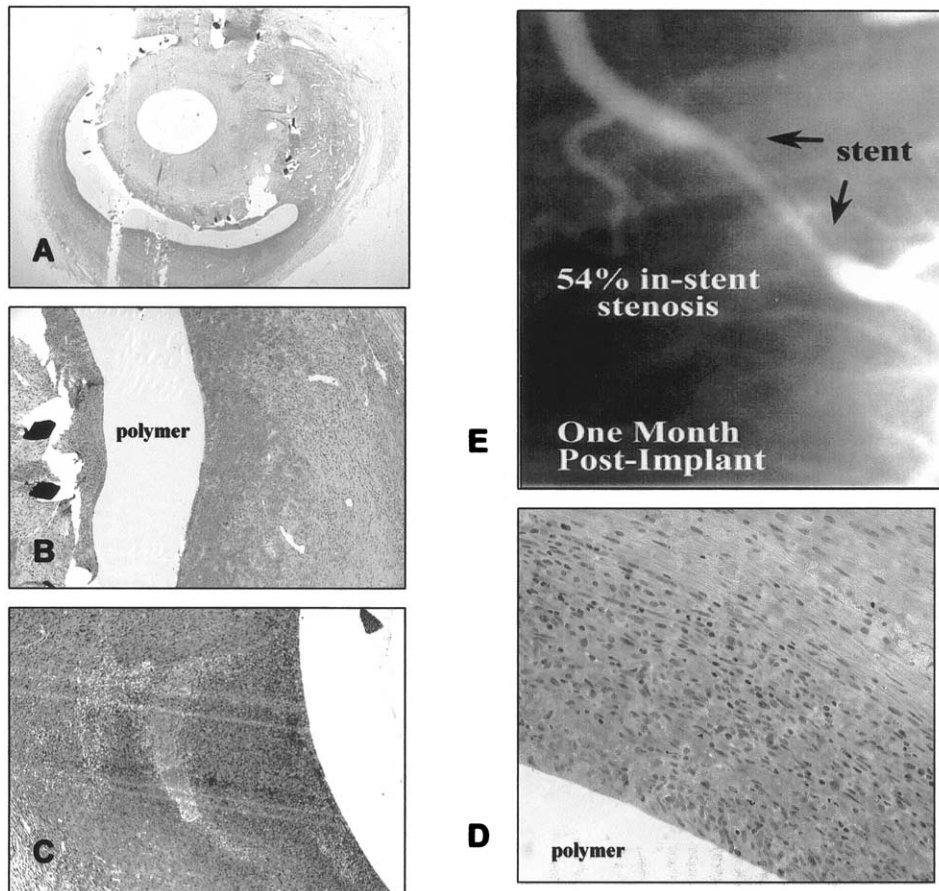


Figure 6. Photomicrographs of porcine coronary arteries at 28 days after the implantation of Quannum-DS (Quanam Medical Corp., Santa Clara, California) stents. These images show neointimal stimulation by high-dose taxane in these stents. Similar results occurred in the SCORE clinical trial. Low power histomorphometry of mid-stent cross-section shows marked vessel lumen narrowing from neointimal hyperplasia. (B, C, and D) Rampant inflammation at sites of the polymer-drug combination in these vessels is shown. Several areas of granuloma and hemorrhage (B) are present. The inflammation was likely a major cause of the neointimal thickening. (E) Cine-film frame of Quannum stent showing marked in-stent restenosis.

translation may not be as direct as desired, and the quantitative relationship between neointima in the porcine model and in patients remains poorly defined.

At least two DESs (rapamycin and paclitaxel) show convincing restenosis efficacy in patients. Both use a compatible polymer for controlled drug release. Suzuki et al. (100) examined rapamycin-eluting stents and compared them with bare stents, dexamethasone-eluting, and both rapamycin-eluting and dexamethasone-eluting devices. The rapamycin-eluting stents reduced in-stent neointimal hyperplasia at 28 days with a mean neointimal area of 2.47 mm² (rapamycin alone), 2.42 mm² (rapamycin and dexamethasone), 5.06 mm² (bare stent), and 4.31 mm² (dexamethasone alone). Gallo et al. (150) examined intramuscular rapamycin given to pigs for 14 days after balloon-induced injury. The animals were studied 28 days after percutaneous transluminal coronary angioplasty and showed coronary stenoses of 63% and 36%, respectively (lumen area 1.74 mm² vs. 3.3 mm²; control vs. rapamycin). These two preclinical studies suggest that rapamycin has efficacy against neointimal formation in the porcine artery injury model, a suggestion that was confirmed by clinical trials.

Drachman et al. (176) compared paclitaxel-eluting stents with controls in rabbit iliac arteries after balloon denudation. These investigators found that paclitaxel-eluting stents markedly inhibited neointimal thickening at all late time points and concluded this technology was effective against neointima beyond the time of paclitaxel elution.

Preclinical porcine data used for regulatory submission of the TAXUS stent (Boston Scientific, Natick, Massachusetts) showed the device was safe but also showed no significant efficacy reducing neointima at 28 or 90 days compared with bare metal stents. TAXUS stent clinical data show excellent results at nine months for limiting restenosis (177). Earlier studies of the TAXUS stent are now in their third year and show major adverse clinical event rates of 3% compared with 10% in bare-metal stents. The comparable porcine model data show no change at 180 days from 90 days (unpublished data, personal communications). These crude comparisons suggest that safety, but not efficacy, can be predicted from low-level stent injury (balloon:artery ratio 1.1:1 or less) in the porcine model. Further analysis of paclitaxel animal model data and possibly new models may find application in better predicting clinical efficacy.

SUMMARY

What have we learned from animal restenosis models?

Several important principles summarize restenosis models for evaluating DES technologies. These are as follows:

1. Arterial and vascular injuries remain major determinants of neointimal thickening, and mechanical stent designs should limit arterial injury as best as possible.
2. Neointimal formation on DESs develops the same as in bare-metal stents. Thrombus and inflammation play key roles in forming human neointimal hyperplasia, and the polymers used in drug eluting stents incite mild inflammation. Optimal polymer selection may help to minimize this inflammation, and healing within DESs should be documented.
3. Although DESs limit neointimal formation, they may also delay or cause incomplete healing to a greater degree than in bare-metal stents. This is manifested clinically as incomplete endothelialization, unresorbed fibrin deposits, and drug effects typically consisting of hypocellular tissue near the drug-eluting struts. Because neointimal hyperplasia is a normal healing response, some degree of neointima, not obstructive to the lumen, is a desirable outcome for DESs.
4. Animal models, specifically the porcine coronary and rabbit iliac arteries, provide useful information regarding stent thrombosis risk in clinical trials and are thus a measure of safety. All animal studies should carefully determine causes of unexpected preclinical animal deaths, and tabulate stent thrombotic events.
5. Lumen loss in animal models results from several causes. These include medial or arterial cell death, inflammation, and neointimal thickening, results that have correlation in clinical trials. Poor preclinical results mandate strong caution in initiating clinical trials.
6. Efficacy testing in preclinical models has proven difficult to establish. It is unclear whether this is because current animal models do not accurately reflect the human coronary artery response to such stents or whether other causes need be sought. Prior preclinical studies with positive results that did not translate to patients may be due to improper or biased variable selection, or confounding effects of vascular injury.

What must yet be learned from animal restenosis models?

The science of preclinical restenosis models is a rapidly developing field and is undergoing intense study. What follows are several key but unanswered questions concerning restenosis models.

Incompletely healed vessels occur in the preclinical DES models. The importance of healing, with incomplete or absent endothelialization, unresorbed fibrin deposits, low-level inflammation, and medial cell dropout is not well understood. For example, the porcine coronary artery safety appears predictive of clinical safety. Actinomycin-D-eluting stents showed nonhealing to a large degree, stimulating

porcine neointima. It is uncertain whether improved-yet-incomplete healing will similarly enhance neointimal formation.

The best variables to correlate preclinical models with clinical trials are unknown. Correlative research must be performed to determine which preclinical variables best translate quantitatively to clinical trials. Clarification of whether quantitative measurements of MLD, late loss/loss index, and IVUS-based measurements of neointima in the porcine model will translate well, or if at all, to clinical data. Careful preclinical studies should be conducted for comparison with clinical trials. It is suggested in the interim that angiographic and IVUS end points may best for study in patients, and these combined with histomorphometric data in animal trials should be the best obtainable.

The relative utility of different species is uncertain. Differences between rabbit and pig models must be examined to determine which best translate to patients. This point is key in the prediction of human clinical data from preclinical studies, and we must better understand whether safety (thrombosis and neointimal stimulation) translate for each model to clinical trials.

The optimal time point for termination in animal studies needs clarification to best predict human clinical results. Standard times for animal models are 28, 90, 180, or 365 days, and early positive animal data may become negative at later time points. The time course of arterial healing in animal models bears an uncertain relationship to patients and also must be better understood so that preclinical observations will yield accurate prediction for clinical trials with patient data. Model data at two-year to three-year time points may need examination and correlation with clinical results for accuracy. Additional time points may be important, but presently no clear answer is forthcoming. The time to endothelial recovery for different drug/polymer/stent configurations in injured vessels remains unknown and needs determination.

Several preclinical model enhancements are needed. More rapid turnaround time would be of substantial benefit because current preclinical data can take nine months or longer to process and evaluate. It may be possible that preclinical histomorphometric data (neointimal thickness, histopathologic percent stenosis, lumen size) can be predicted from preclinical quantitative coronary angiography and IVUS in the same animal pre-mortem or post-mortem. These parameters might provide a link with human data, and if true would be a major contribution to research and development in drug eluting stents.

Preclinical models are important but imperfect standards, having served the interventional community well for many years. Substantially more remains to be learned, especially regarding the positive predictive results in such models. Active research is aimed at developing a simple, inexpensive, rapid, and accurate preclinical model for human restenosis. This goal is achievable but will require thoughtful direction. Such a model will see rapid adoption for testing, evaluating, and

prediction and will continue to teach the interventional community important lessons about revascularization therapy.

Reprint requests and correspondence: Dr. Robert S. Schwartz, Minneapolis Heart Institute, Minnesota Cardiovascular Research Institute, 920 East 28th Street, Suite 300, Minneapolis, Minnesota 55407. E-mail: rss@rsschwartz.com.

REFERENCES

1. Carter AJ, Laird JR, Farb A, Kufs W, Wortham DC, Virmani R. Morphologic characteristics of lesion formation and time course of smooth muscle cell proliferation in a porcine proliferative restenosis model. *J Am Coll Cardiol* 1994;24:1398-405.
2. Farb A, Sangiorgi G, Carter AJ, et al. Pathology of acute and chronic coronary stenting in humans. *Circulation* 1999;99:44-52.
3. Bayes-Genis A, Kantor B, Keelan PC, et al. Restenosis and hyperplasia: animal models. *Curr Interv Cardiol Rep* 2000;2:303-3.
4. Schwartz R, Holmes DJ. Pigs, dogs, baboons, and man: lessons for stenting from animal studies. *J Intervent Cardiol* 1994;7:355-68.
5. Zempo N, Kenagy RD, Au YP, et al. Matrix metalloproteinases of vascular wall cells are increased in balloon-injured rat carotid artery. *J Vasc Surg* 1994;20:209-17.
6. Zempo N, Koyama N, Kenagy RD, Lea HJ, Clowes AW. Regulation of vascular smooth muscle cell migration and proliferation in vitro and in injured rat arteries by a synthetic matrix metalloproteinase inhibitor. *Arterioscler Thromb Vasc Biol* 1996;16:28-33.
7. Clowes AW, Clowes MM. Kinetics of cellular proliferation after arterial injury. *Lab Invest* 1985;52:611-6.
8. Clowes A, Schwartz S. Significance of quiescent smooth muscle migration in the injured rat carotid artery. *Circ Res* 1985;56:139-45.
9. Clowes AW, Reidy MA, Clowes MM. Mechanisms of stenosis after arterial injury. *Lab Invest* 1983;49:208-15.
10. Lindner V, Reidy MA, Fingerle J. Regrowth of arterial endothelium. Denudation with minimal trauma leads to complete endothelial cell regrowth. *Lab Invest* 1989;61:556-63.
11. Jackson CL, Pettersson KS. Effects of probucol on rat carotid artery responses to balloon catheter injury. *Atherosclerosis* 2001;154:407-14.
12. Lamfers ML, Lardenoye JH, de Vries MR, et al. In vivo suppression of restenosis in balloon-injured rat carotid artery by adenovirus-mediated gene transfer of the cell surface-directed plasmin inhibitor ATF.BPTI. *Gene Ther* 2001;8:534-41.
13. Perlman H, Luo Z, Krasinski K, et al. Adenovirus-mediated delivery of the Gax transcription factor to rat carotid arteries inhibits smooth muscle proliferation and induces apoptosis. *Gene Ther* 1999;6:758-63.
14. Ascher E, Scheinman M, Hingorani A, et al. Effect of p53 gene therapy combined with CTLA4Ig selective immunosuppression on prolonged neointima formation reduction in a rat model. *Ann Vasc Surg* 2000;14:385-92.
15. Powell J, Clozel JP, Muller RK, et al. Inhibitors of angiotensin-converting enzyme prevent myointimal proliferation after vascular injury. *Science* 1989;245:186-8.
16. Powell JS, Muller RK, Rouge M, et al. The proliferative response to vascular injury is suppressed by angiotensin-converting enzyme inhibition. *J Cardiovasc Pharmacol* 1990;16 Suppl 4:S42-9.
17. Faxon DP. Angiotensin converting enzyme inhibition and restenosis: the final results of the MARCATOR trial (abstr). *Circulation* 1992;86:I53.
18. Berger PB, Holmes DR Jr., Ohman EM, et al. Restenosis, reocclusion and adverse cardiovascular events after successful balloon angioplasty of occluded versus non-occluded coronary arteries. Results from the Multicenter American Research Trial With Cilazapril After Angioplasty to Prevent Transluminal Coronary Obstruction and Restenosis (MARCATOR). *J Am Coll Cardiol* 1996;27:1-7.
19. Serruys P, Hermans R. The new angiotensin converting enzyme inhibitor cilazapril does not prevent restenosis after coronary angioplasty: the results of the MERCATOR trial (abstr). *J Am Coll Cardiol* 1992;19:258A.
20. Peters S, Gotting B, Trummel M, Rust H, Brattstrom A. Valsartan for prevention of restenosis after stenting of type B2/C lesions: the VAL-PREST trial. *J Invasive Cardiol* 2001;13:93-7.
21. Matsumoto K, Morishita R, Moriguchi A, et al. Inhibition of neointima by angiotensin-converting enzyme inhibitor in porcine coronary artery balloon-injury model. *Hypertension* 2001;37:270-4.
22. Ellis SG. Do ACE inhibitors or ARBs limit restenosis after stenting? Assimilating the data. *J Invasive Cardiol* 2001;13:98-9.
23. Sata M, Maejima Y, Adachi F, et al. A mouse model of vascular injury that induces rapid onset of medial cell apoptosis followed by reproducible neointimal hyperplasia. *J Mol Cell Cardiol* 2000;32:2097-104.
24. Horiba M, Kadomatsu K, Nakamura E, et al. Neointima formation in a restenosis model is suppressed in midkine-deficient mice. *J Clin Invest* 2000;105:489-95.
25. Lindner V. Vascular repair processes mediated by transforming growth factor-beta. *Z Kardiol* 2001;90 Suppl 3:17-22.
26. Lindner V, Collins T. Expression of NF-kappa B and I kappa B-alpha by aortic endothelium in an arterial injury model. *Am J Pathol* 1996;148:427-38.
27. Lindner V, Giachelli CM, Schwartz SM, Reidy MA. A subpopulation of smooth muscle cells in injured rat arteries expresses platelet-derived growth factor-B chain mRNA. *Circ Res* 1995;76:951-7.
28. Lindner V, Reidy MA. Expression of VEGF receptors in arteries after endothelial injury and lack of increased endothelial regrowth in response to VEGF. *Arterioscler Thromb Vasc Biol* 1996;16:1399-405.
29. Kalinowski M, Alfke H, Bergen S, Klose KJ, Barry JJ, Wagner HJ. Comparative trial of local pharmacotherapy with L-arginine, r-hirudin, and molsidomine to reduce restenosis after balloon angioplasty of stenotic rabbit iliac arteries. *Radiology* 2001;219:716-23.
30. Nagae T, Aizawa K, Uchimura N, et al. Endovascular photodynamic therapy using mono-L-aspartyl-chlorin e6 to inhibit intimal hyperplasia in balloon-injured rabbit arteries. *Lasers Surg Med* 2001;28:381-8.
31. Kanamasa K, Otani N, Ishida N, et al. A 7-day administration of tPA or heparin in the prevention of internal hyperplasia following vascular injury in atherosclerotic rabbits. *J Interv Cardiol* 2002;15:191-5.
32. Steinhubl SR, Ellis SG, Wolski K, Lincoff AM, Topol EJ. Ticlopidine pretreatment before coronary stenting is associated with sustained decrease in adverse cardiac events: data from the Evaluation of Platelet IIb/IIIa Inhibitor for Stenting Trial (EPISTENT). *Circulation* 2001;103:1403-9.
33. Nagaoka N, Matsubara T, Okazaki K, Masuda N, Shikaura K, Hotta A. Comparison of ticlopidine and cilostazol for the prevention of restenosis after percutaneous transluminal coronary angioplasty. *Jpn Heart J* 2001;42:43-54.
34. Schwartz RS, Murphy JG, Edwards WD, Camrud AR, Vliestra RE, Holmes DR. Restenosis after balloon angioplasty: a practical proliferative model in porcine coronary arteries. *Circulation* 1990;82:2190-200.
35. Schwartz R, Huber K, Murphy J, et al. Restenosis and the proportional neointimal response to coronary artery injury: results in a porcine model. *J Am Coll Cardiol* 1992;19:267-74.
36. Schwartz RS, Huber KC, Murphy JG, et al. Restenosis and the proportional neointimal response to coronary artery injury: results in a porcine model. *J Am Coll Cardiol* 1992;19:267-74.
37. Rodgers GP, Minor ST, Robinson K, et al. Adjuvant therapy for intracoronary stents. Investigations in atherosclerotic swine. *Circulation* 1990;82:560-9.
38. Rodgers GP, Minor ST, Robinson K, et al. The coronary artery response to implantation of a balloon-expandable flexible stent in the aspirin- and non-aspirin-treated swine model. *Am Heart J* 1991;122:640-7.
39. Schwartz R, Holder DJ, Holmes DR, et al. Neointimal thickening after severe coronary artery injury is limited by short term administration of a factor xa inhibitor: results in a porcine model. *Circulation* 1996;83:1542-8.
40. Schwartz RS, Topol EJ, Serruys PW, Sangiorgi G, Holmes DR Jr. Artery size, neointima, and remodeling: time for some standards. *J Am Coll Cardiol* 1998;32:2087-94.
41. Huber KC, Schwartz RS, Edwards WD, et al. Effects of angiotensin converting enzyme inhibition on neointimal hyperplasia in a porcine coronary injury model. *Am Heart J* 1993;125:695-701.

42. Schwartz RS, Koval TM, Edwards WD, et al. Effect of external beam irradiation on neointimal hyperplasia after experimental coronary artery injury. *J Am Coll Cardiol* 1992;19:1106-13.
43. Kim W, Jeong MH, Park OY, et al. Effects of beta-radiation using a holmium-166 coated balloon on neointimal hyperplasia in a porcine coronary stent restenosis model. *Circ J* 2003;67:625-9.
44. Ajani AE, Cheneau E, Leborgne L, Wolfram R, Waksman R. Have we solved the problem of late thrombosis? *Minerva Cardioangiol* 2002;50:463-8.
45. Crocker I, Robinson KA. Rationale for coronary artery radiation therapy. *Semin Radiat Oncol* 2002;12:3-16.
46. Fischell TA, Virmani R. Intracoronary brachytherapy in the porcine model: a different animal. *Circulation* 2001;104:2388-90.
47. Virmani R, Farb A, Carter AJ, Jones RM. Pathology of radiation-induced coronary artery disease in human and pig. *Cardiovasc Radiat Med* 1999;1:98-101.
48. Carter AJ, Jenkins S, Sweet W, et al. Dose and dose rate effects of beta-particle emitting radioactive stents in a porcine model of restenosis. *Cardiovasc Radiat Med* 1999;1:327-35.
49. Vodovotz Y, Waksman R, Kim WH, et al. Effects of intracoronary radiation on thrombosis after balloon overstretch injury in the porcine model. *Circulation* 1999;100:2527-33.
50. Carter AJ, Laird JR. Experimental results with endovascular irradiation via a radioactive stent. *Int J Radiat Oncol Biol Phys* 1996;36:797-803.
51. Waksman R. Local catheter-based intracoronary radiation therapy for restenosis. *Am J Cardiol* 1996;78:23-8.
52. Saia F, Sianos G, Hoye A, et al. Long-term outcome of percutaneous coronary interventions following failed beta-brachytherapy. *J Invasive Cardiol* 2004;16:60-4.
53. Dixon SR, Grines CL, Safian RD. Coronary artery pseudoaneurysm after balloon angioplasty and intracoronary beta-radiation for in-stent restenosis. *Catheter Cardiovasc Interv* 2004;61:214-6.
54. Naber CK, Baumgart D, Bonan R, et al. Intracoronary brachytherapy, a promising treatment option for diabetic patients: results from a European multicenter registry (RENO). *Catheter Cardiovasc Interv* 2004;61:173-8.
55. Shirai K, Lansky AJ, Mintz GS, et al. Comparison of the angiographic outcomes after beta versus gamma vascular brachytherapy for treatment of in-stent restenosis. *Am J Cardiol* 2003;92:1409-13.
56. Sianos G, Wijns W, de Feyter PJ, Serruys PW. Geographical miss during centered intracoronary beta-radiation with ⁹⁰Yttrium: incidence and implications for recurrence rates after vascular brachytherapy for de novo lesions. *Int J Cardiovasc Intervent* 2003;5:181-9.
57. Doriot PA, Dorsaz PA, Verin V. A morphological-mechanical explanation of edge restenosis in lesions treated with vascular brachytherapy. *Cardiovasc Radiat Med* 2003;4:108-15.
58. Waksman R, Raizner A, Popma JJ. Beta emitter systems and results from clinical trials. *State of the art. Cardiovasc Radiat Med* 2003;4:54-63.
59. Farb A, Burke AP, Kolodgie FD, Virmani R. Pathological mechanisms of fatal late coronary stent thrombosis in humans. *Circulation* 2003;108:1701-6.
60. Suntharalingam M, Laskey WK, Tantibhedhyangkul W, et al. Vascular brachytherapy using a beta emitter source in diabetic patients with in-stent restenosis: angiographic and clinical outcomes. *Int J Radiat Oncol Biol Phys* 2003;57:536-42.
61. Kereiakes DJ, Willerson JT. Vascular brachytherapy boon or bust? *Circulation* 2003;108:389-90.
62. Waksman R, Weinberger J. Coronary brachytherapy in the drug-eluting stent era: don't bury it alive. *Circulation* 2003;108:386-8.
63. Erl W, Hristov M, Neureuter M, Yan ZQ, Hansson GK, Weber PC. HMG-CoA reductase inhibitors induce apoptosis in neointima-derived vascular smooth muscle cells. *Atherosclerosis* 2003;169:251-8.
64. Walter DH, Fichtlscherer S, Britten MB, et al. Statin therapy, inflammation and recurrent coronary events in patients following coronary stent implantation. *J Am Coll Cardiol* 2001;38:2006-12.
65. Malik IS, Khan M, Beatt KJ. Effect of statin therapy on restenosis after coronary stent implantation. *Am J Cardiol* 2000;86:810.
66. Walter DH, Schachinger V, Elsner M, Mach S, Auch-Schweik W, Zeiher AM. Effect of statin therapy on restenosis after coronary stent implantation. *Am J Cardiol* 2000;85:962-8.
67. Serruys PW, Foley DP, Jackson G, et al. A randomized placebo-controlled trial of fluvastatin for prevention of restenosis after successful coronary balloon angioplasty; final results of the fluvastatin angiographic restenosis (FLARE) trial. *Eur Heart J* 1999;20:58-69.
68. Faxon DP. Effect of high dose angiotensin-converting enzyme inhibition on restenosis: final results of the MARCATOR Study, a multicenter, double-blind, placebo-controlled trial of cilazapril. The Multicenter American Research Trial With Cilazapril After Angioplasty to Prevent Transluminal Coronary Obstruction and Restenosis (MARCATOR) Study Group. *J Am Coll Cardiol* 1995;25:362-9.
69. Wilson DP, Saward L, Zahradka P, Cheung PK. Angiotensin II receptor antagonists prevent neointimal proliferation in a porcine coronary artery organ culture model. *Cardiovasc Res* 1999;42:761-72.
70. Huckle WR, Drag MD, Acker WR, et al. Effects of subtype-selective and balanced angiotensin II receptor antagonists in a porcine coronary artery model of vascular restenosis. *Circulation* 1996;93:1009-19.
71. Becker RH. ACE inhibition and atherosclerosis in the animal model. *Z Kardiol* 1994;83 Suppl 4:15-20.
72. Hanson SR, et al. Effects of angiotensin converting enzyme inhibition with cilazapril on intimal hyperplasia in injured arteries and vascular grafts in the baboon. *Hypertension* 1991;18 Suppl 4:II70-6.
73. Sasseen BM, Gray BD, Gal D, et al. Local delivery of a hydrophobic heparin reduces neointimal hyperplasia after balloon injury in rat carotid but not pig coronary arteries. *J Cardiovasc Pharmacol Ther* 2001;6:377-83.
74. Matsumoto Y, Shimokawa H, Morishige K, Eto Y, Takeshita A. Reduction in neointimal formation with a stent coated with multiple layers of releasable heparin in porcine coronary arteries. *J Cardiovasc Pharmacol* 2002;39:513-22.
75. Goodwin SC, Yoon HC, Wong GC, Bonilla SM, Vedantham S, Arora LC. Percutaneous delivery of a heparin-impregnated collagen stent-graft in a porcine model of atherosclerotic disease. *Invest Radiol* 2000;35:420-5.
76. Ahn YK, Jeong MH, Kim JW, et al. Preventive effects of the heparin-coated stent on restenosis in the porcine model. *Catheter Cardiovasc Interv* 1999;48:324-30.
77. Nugent HM, Rogers C, Edelman ER. Endothelial implants inhibit intimal hyperplasia after porcine angioplasty. *Circ Res* 1999;84:384-91.
78. Kornowski R, Hong MK, Tio FO, Choi SK, Bramwell O, Leon MB. A randomized animal study evaluating the efficacies of locally delivered heparin and urokinase for reducing in-stent restenosis. *Coron Artery Dis* 1997;8:293-8.
79. Abendschein DR, Recchia D, Meng YY, Oltrona L, Wickline SA, Eisenberg PR. Inhibition of thrombin attenuates stenosis after arterial injury in minipigs. *J Am Coll Cardiol* 1996;28:1849-55.
80. Ali MN, Mazur W, Kleiman NS, et al. Inhibition of coronary restenosis by antithrombin III in atherosclerotic swine. *Coron Artery Dis* 1996;7:851-61.
81. Buchwald AB, Hammerschmidt S, Stevens J, Goring J, Nebendahl K, Unterberg C. Inhibition of neointimal proliferation after coronary angioplasty by low-molecular-weight heparin (clivarine) and polyethyleneglycol-hirudin. *J Cardiovasc Pharmacol* 1996;28:481-7.
82. Emanuelsson H, Serruys PW, van Der Giessen WJ, et al. Clinical and Angiographic Results with the Multi-Link feminine Coronary Stent System N The West European Stent Trial (WEST). *J Invasive Cardiol* 1998;10 Suppl B:12B-9B.
83. Gobel FL, Mooney MR, Graham KJ. Coronary artery bypass graft degenerative disease. *Curr Treat Options Cardiovasc Med* 2001;3:47-54.
84. Morice MC, Zemor G, Benveniste E, et al. Intracoronary stenting without coumadin: one month results of a French multicenter study. *Cathet Cardiovasc Diagn* 1995;35:1-7.
85. Nakamura S, Hall P, Gaglione A, et al. High pressure assisted coronary stent implantation accomplished without intravascular ultrasound guidance and subsequent anticoagulation. *J Am Coll Cardiol* 1997;29:21-7.
86. Serruys PW, Emanuelsson H, van der Giessen W, et al. Heparin-coated Palmaz-Schatz stents in human coronary arteries. Early outcome of the Benestent-II Pilot Study. *Circulation* 1996;93:412-22.

87. Thornton MA, Gruentzig AR, Hollman J, King SB 3rd, Douglas JS. Coumadin and aspirin in prevention of recurrence after transluminal coronary angioplasty: a randomized study. *Circulation* 1984;69:721-727.
88. Lau AK, Leichtweis SB, Hume P, et al. Probucol promotes functional reendothelialization in balloon-injured rabbit aortas. *Circulation* 2003;107:2031-6.
89. Inoue K, Cynshi O, Kawabe Y, et al. Effect of BO-653 and probucol on c-MYC and PDGF-A messenger RNA of the iliac artery after balloon denudation in cholesterol-fed rabbits. *Atherosclerosis* 2002;161:353-63.
90. Jackson CL, Pettersson KS. Effects of probucol on rat carotid artery responses to balloon catheter injury. *Atherosclerosis* 2001;154:407-14.
91. Nagao S, Yamaguchi T, Kasahara M, et al. Effect of probucol in a murine model of slowly progressive polycystic kidney disease. *Am J Kidney Dis* 2000;35:221-6.
92. Cote G, Tardif JC, Lesperance J, et al. Effects of probucol on vascular remodeling after coronary angioplasty. Multivitamins and Protocol Study Group. *Circulation* 1999;99:30-5.
93. Miyauchi K, Aikawa M, Tani T, et al. Effect of probucol on smooth muscle cell proliferation and dedifferentiation after vascular injury in rabbits: possible role of PDGF. *Cardiovasc Drugs Ther* 1998;12:251-60.
94. Tanaka K, Hayashi K, Shingu T, Kuga Y, Nomura K, Kajiyama G. Probucol inhibits neointimal formation in carotid arteries of normocholesterolemic rabbits and the proliferation of cultured rabbit vascular smooth muscle cells. *Cardiovasc Drugs Ther* 1998;12:19-28.
95. Tardif JC, Gregoire J, L'Allier PL. Prevention of restenosis with antioxidants: mechanisms and implications. *Am J Cardiovasc Drugs* 2002;2:323-34.
96. Yokoi H, Daida H, Kuwabara Y, et al. Effectiveness of an antioxidant in preventing restenosis after percutaneous transluminal coronary angioplasty: the Probucol Angioplasty Restenosis Trial. *J Am Coll Cardiol* 1997;30:855-62.
97. Sirtori CR, Franceschini G. Probucol and multivitamins in the prevention of restenosis after coronary angioplasty. *N Engl J Med* 1997;337:1918; author reply, 1919.
98. Castro C, Campistol JM, Sancho D, Sanchez-Madrid F, Casals E, Andres V. Rapamycin attenuates atherosclerosis induced by dietary cholesterol in apolipoprotein-deficient mice through a p27 Kip1-independent pathway. *Atherosclerosis* 2004;172:31-8.
99. Basso MD, Nambi P, Adelman SJ. Effect of sirolimus on the cholesterol content of aortic arch in ApoE knockout mice. *Transplant Proc* 2003;35:3136-8.
100. Suzuki T, Kopia G, Hayashi S, et al. Stent-based delivery of sirolimus reduces neointimal formation in a porcine coronary model. *Circulation* 2001;104:1188-93.
101. Mack MJ. Sirolimus-eluting coronary stents. *N Engl J Med* 2004;350:413-4; author reply, 413-4.
102. Schofer J, Schluter M, Gershlick AH, et al. Sirolimus-eluting stents for treatment of patients with long atherosclerotic lesions in small coronary arteries: double-blind, randomised controlled trial (E-SIRIUS). *Lancet* 2003;362:1093-9.
103. Marks AR. Sirolimus for the prevention of in-stent restenosis in a coronary artery. *N Engl J Med* 2003;349:1307-9.
104. Moses JW, Leon MB, Popma JJ, et al. Sirolimus-eluting stents versus standard stents in patients with stenosis in a native coronary artery. *N Engl J Med* 2003;349:1315-23.
105. Drenth DJ, Zijlstra F, Boonstra PW. Sirolimus-eluting coronary stents. *N Engl J Med* 2004;350:413-4; author reply, 413-4.
106. Scheller B, Speck U, Schmitt A, Bohm M, Nickenig G. Addition of paclitaxel to contrast media prevents restenosis after coronary stent implantation. *J Am Coll Cardiol* 2003;42:1415-20.
107. Hong MK, Kornowski R, Bramwell O, Ragheb AO, Leon MB. Paclitaxel-coated Gianturco-Roubin II (GR II) stents reduce neointimal hyperplasia in a porcine coronary in-stent restenosis model. *Coron Artery Dis* 2001;12:513-5.
108. Oberhoff M, Herdeg C, Al Ghobainy R, et al. Local delivery of paclitaxel using the double-balloon perfusion catheter before stenting in the porcine coronary artery. *Catheter Cardiovasc Interv* 2001;53:562-8.
109. Heldman AW, Cheng L, Jenkins GM, et al. Paclitaxel stent coating inhibits neointimal hyperplasia at 4 weeks in a porcine model of coronary restenosis. *Circulation* 2001;103:2289-95.
110. Hou D, Rogers PI, Toleikis PM, Hunter W, March KL. Intrapericardial paclitaxel delivery inhibits neointimal proliferation and promotes arterial enlargement after porcine coronary overstretch. *Circulation* 2000;102:1575-81.
111. Serruys PW, Degertekin M, Tanabe K, et al. Vascular responses at proximal and distal edges of paclitaxel-eluting stents: serial intravascular ultrasound analysis from the TAXUS II trial. *Circulation* 2004;109:627-33.
112. Silber S. Paclitaxel-eluting stents: are they all equal? An analysis of six randomized controlled trials in de novo lesions of 3,319 patients. *J Interv Cardiol* 2003;16:485-90.
113. Bhatia V, Bhatia R, Dhindsa S. Drug-eluting intra-coronary stents: have we got the magic bullet? *J Postgrad Med* 2003;49:291-6.
114. Park SJ, Shim WH, Ho DS, et al. A paclitaxel-eluting stent for the prevention of coronary restenosis. *N Engl J Med* 2003;348:1537-45.
115. Tanabe K, Serruys PW, Grube E, et al. TAXUS III trial: in-stent restenosis treated with stent-based delivery of paclitaxel incorporated in a slow-release polymer formulation. *Circulation* 2003;107:559-64.
116. Ide S, Kondoh M, Satoh H, Karasawa A. Anti-proliferative effects of benidipine hydrochloride in porcine cultured vascular smooth muscle cells and in rats subjected to balloon catheter-induced endothelial denudation. *Biol Pharm Bull* 1994;17:627-31.
117. Hoberg E, Kubler W. Prevention of restenosis after PTCA: role of calcium antagonists. *J Cardiovasc Pharmacol* 1991;18 Suppl 6: S15-9.
118. Hoberg E, Kubler W. Calcium-antagonists in preventing restenosis following coronary angioplasty. *Cardiologia* 1991;36:12 Suppl 1:225-7.
119. Hoberg E. The effects of calcium antagonists after PTCA (review). *Eur Heart J* 1995;16 Suppl H:9-12.
120. Kipshidze NN, Kim HS, Iversen P, et al. Intramural coronary delivery of advanced antisense oligonucleotides reduces neointimal formation in the porcine stent restenosis model. *J Am Coll Cardiol* 2002;39:1686-91.
121. Shi Y, Fard A, Galeo A, et al. Transcatheter delivery of c-myc antisense oligomers reduces neointimal formation in a porcine model of coronary artery balloon injury. *Circulation* 1994;90:944-51.
122. Freedman SB. Clinical trials of gene therapy for atherosclerotic cardiovascular disease. *Curr Opin Lipidol* 2002;13:653-61.
123. Lee M, Simon AD, Stein CA, Rabbani LE. Antisense strategies to inhibit restenosis. *Antisense Nucleic Acid Drug Dev* 1999;9:487-92.
124. Kallinteri P, Antimisiaris SG, Karnabatidis D, Kalogeropoulou C, Tsota I, Siablis D. Dexamethasone incorporating liposomes: an in vitro study of their applicability as a slow releasing delivery system of dexamethasone from covered metallic stents. *Biomaterials* 2002;23:4819-26.
125. Lincoff AM, Furst JG, Ellis SG, Tuch RJ, Topol EJ. Sustained local delivery of dexamethasone by a novel intravascular eluting stent to prevent restenosis in the porcine coronary injury model. *J Am Coll Cardiol* 1997;29:808-16.
126. Radke PW, Weber C, Kaiser A, Schober A, Hoffmann R. Dexamethasone and restenosis after coronary stent implantation: new indication for an old drug (review)? *Curr Pharm Des* 2004;10:349-55.
127. Liu X, Huang Y, Hanet C, et al. Study of antirestenosis with the BiodivYsio dexamethasone-eluting stent (STRIDE): a first-in-human multicenter pilot trial. *Catheter Cardiovasc Interv* 2003;60:172-8; discussion, 179.
128. Duda SH, Poerner TC, Wiesinger B. Drug-eluting stents: potential applications for peripheral arterial occlusive disease. *J Vasc Interv Radiol* 2003;14:291-301.
129. Baumbach A, Oberhoff M, Herdeg C, et al. Local delivery of a low molecular weight heparin following stent implantation in the pig coronary artery. *Basic Res Cardiol* 2000;95:173-8.
130. Jenkins JS, Weibel R, Laughlin MH, et al. Restenosis following placement of an intracoronary heparin treated tantalum stent in the hyperlipidemic miniature swine model. *J Invasive Cardiol* 1995;7:173-82.
131. Franck H, Weber K, Pieper MJ, Frese W. Local heparin delivery for prevention of second in-stent restenosis. Acute and long-term results in 47 consecutive cases. *Int J Cardiovasc Intervent* 2000;3:181-4.

132. Kereiakes DJ. Adjunctive pharmacotherapy before percutaneous coronary intervention in non-ST-elevation acute coronary syndromes: the role of modulating inflammation. *Circulation* 2003;108:1 Suppl 1:III22-7.
133. Haude M, Konorza TF, Kalnins U, et al. Heparin-coated stent placement for the treatment of stenoses in small coronary arteries of symptomatic patients. *Circulation* 2003;107:1265-70.
134. Virmani R, Farb A. Pathology of in-stent restenosis. *Curr Opin Lipidol* 1999;10:499-506.
135. Taylor AJ, Gorman PD, Kenwood B, Hudak C, Tashko G, Virmani R. comparison of four stent designs on arterial injury, cellular proliferation, neointima formation, and arterial dimensions in an experimental porcine model. *Catheter Cardiovasc Interv* 2001;53:420-5.
136. Virmani R, Kolodgie FD, Farb A, Lafont A. Drug eluting stents: are human and animal studies comparable? *Heart* 2003;89:133-8.
137. Kim WH, Hong MK, Virmani R, Kornowski R, Jones R, Leon MB. Histopathologic analysis of in-stent neointimal regression in a porcine coronary model. *Coron Artery Dis* 2000;11:273-7.
138. Schwartz RS, Henry TD. Pathophysiology of coronary artery restenosis. *Rev Cardiovasc Med* 2002;3 Suppl 5:S4-9.
139. Schwartz RS. Characteristics of an ideal stent based upon restenosis pathology. *J Invasive Cardiol* 1996;8:386-7.
140. Bayes-Genis A, Campbell JH, Carlson PJ, Holmes DR Jr., Schwartz RS. Macrophages, myofibroblasts and neointimal hyperplasia after coronary artery injury and repair. *Atherosclerosis* 2002;163:89-98.
141. Ishiwata S, Verheye S, Robinson KA, et al. Inhibition of neointima formation by tranilast in pig coronary arteries after balloon angioplasty and stent implantation. *J Am Coll Cardiol* 2000;35:1331-7.
142. Rogers C, Edelman ER, Simon DI. A mAb to the beta2-leukocyte integrin Mac-1 (CD11b/CD18) reduces intimal thickening after angioplasty or stent implantation in rabbits. *Proc Natl Acad Sci USA* 1998;95:10134-9.
143. Kornowski R, Hong MK, Tio FO, Bramwell O, Wu H, Leon MB. In-stent restenosis: contributions of inflammatory responses and arterial injury to neointimal hyperplasia. *J Am Coll Cardiol* 1998;31:224-30.
144. Karnik SK, Brooke BS, Bayes-Genis A, et al. A critical role for elastin signaling in vascular morphogenesis and disease. *Development* 2003;130:411-23.
145. Schwartz RS, Chu A, Edwards WD, et al. A proliferation analysis of arterial neointimal hyperplasia: lessons for antiproliferative restenosis therapies. *Int J Cardiol* 1996;53:71-80.
146. Kwon HM, Sangiorgi G, Ritman EL, et al. Adventitial vasa vasorum in balloon-injured coronary arteries: visualization and quantitation by a microscopic three-dimensional computed tomography technique. *J Am Coll Cardiol* 1998;32:2072-9.
147. Humar R, Kiefer FN, Berns H, Resink TJ, Battagay EJ. Hypoxia enhances vascular cell proliferation and angiogenesis in vitro by rapamycin (mTOR)-dependent signaling. *FASEB J* 2002;16:771-80.
148. Fuchs S, Kornowski R, Leon MB, Epstein SE. Anti-angiogenesis: a new potential strategy to inhibit restenosis. *Int J Cardiovasc Intervent* 2001;4:3-6.
149. Sata M, Takahashi A, Tanaka K, et al. Mouse genetic evidence that tranilast reduces smooth muscle cell hyperplasia via a p21(WAF1)-dependent pathway. *Arterioscler Thromb Vasc Biol* 2002;22:1305-9.
150. Gallo R, Padurean A, Jayaraman T, et al. Inhibition of intimal thickening after balloon angioplasty in porcine coronary arteries by targeting regulators of the cell cycle. *Circulation* 1999;99:2164-70.
151. Lamphere L, Tsui L, Wick S, et al. Novel chimeric p16 and p27 molecules with increased antiproliferative activity for vascular disease gene therapy. *J Mol Med* 2000;78:451-9.
152. Morishita R, Gibbons GH, Ellison KE, et al. Antisense oligonucleotides directed at cell cycle regulatory genes as strategy for restenosis therapy. *Trans Assoc Am Phys* 1993;106:54-61.
153. Morishita R, Gibbons GH, Kaneda Y, Ogihara T, Dzau VJ. Pharmacokinetics of antisense oligodeoxyribonucleotides (cyclin B1 and CDC 2 kinase) in the vessel wall in vivo: enhanced therapeutic utility for restenosis by HVJ-liposome delivery. *Gene* 1994;149:13-9.
154. von der Leyen H, Gibbons GH, Morishita R, et al. Gene therapy inhibiting neointimal vascular lesion: In vivo transfer of endothelial cell nitric oxide synthase gene. *Proc Natl Acad Sci USA* 1995;92:1137-41.
155. Eigler N, Whiting J, Li A, et al. Effects of a positron-emitting vanadium-48 nitinol stent on experimental restenosis in porcine coronary arteries: an injury-response study. *Cardiovasc Radiat Med* 1999;1:239-51.
156. Axel DI, Kunert W, Goggelmann C, et al. Paclitaxel inhibits arterial smooth muscle cell proliferation and migration in vitro and in vivo using local drug delivery. *Circulation* 1997;96:636-45.
157. Huehns TY, Krausz E, Mrochen S, et al. Neointimal growth can be influenced by local adventitial gene manipulation via a needle injection catheter. *Atherosclerosis* 1999;144:135-50.
158. Hilker M, Buerke M, Guckenbiehl M, et al. Rapamycin reduces neointima formation during vascular injury. *Vasa* 2003;32:10-3.
159. Brara PS, Moussavian M, Grise MA, et al. Pilot trial of oral rapamycin for recalcitrant restenosis. *Circulation* 2003;107:1722-4.
160. Kantor B, Kwon HM, Ritman EL, Holmes DR, Schwartz RS. Images in cardiology imaging the coronary microcirculation: 3D micro-CT of coronary vasa vasorum. *Int J Cardiovasc Intervent* 1999;2:79.
161. Faxon D. Restenosis: do we need to understand it to treat it? *J Am Coll Cardiol* 2002;40:2090-1.
162. Faxon DP. Systemic drug therapy for restenosis: "deja vu all over again." *Circulation* 2002;106:2296-8.
163. Faxon DP, Currier JW. Prevention of post-PTCA restenosis. *Ann N Y Acad Sci* 1995;748:419-27; discussion, 427-8.
164. Fukuyama J, Ichikawa K, Hamano S, Shibata N. Tranilast suppresses the vascular intimal hyperplasia after balloon injury in rabbits fed on a high-cholesterol diet. *Eur J Pharmacol* 1996;318:327-32.
165. Miyazawa K, Fukuyama J, Misawa K, Hamano S, Ujiiie A. Tranilast antagonizes angiotensin II and inhibits its biological effects in vascular smooth muscle cells. *Atherosclerosis* 1996;121:167-73.
166. Kikuchi S, Kikuchi S, Umemura K, Kondo K, Nakashima M. Tranilast suppresses intimal hyperplasia after photochemically induced endothelial injury in the rat. *Eur J Pharmacol* 1996;295:221-7.
167. Holmes DR Jr., Savage M, LaBlanche JM, et al. Results of Prevention of REStenosis with Tranilast and its Outcomes (PRESTO) trial. *Circulation* 2002;106:1243-50.
168. Lafont A, Faxon D. Why do animal models of post-angioplasty restenosis sometimes poorly predict the outcome of clinical trials? *Cardiovasc Res* 1998;39:50-9.
169. Coats WD Jr., Currier JW, Faxon DP. Remodeling and restenosis: insights from animal studies. *Semin Interv Cardiol* 1997;2:153-8.
170. Kaluza GL, Raizner AE, Mazur W, et al. Long-term effects of intracoronary beta-radiation in balloon- and stent-injured porcine coronary arteries. *Circulation* 2001;103:2108-13.
171. Maehara A, Mintz GS, Weissman NJ, et al. Late thrombosis after gamma-brachytherapy. *Catheter Cardiovasc Interv* 2003;58:455-8.
172. Bonvini R, Baumgartner I, Do do D, et al. Late acute thrombotic occlusion after endovascular brachytherapy and stenting of femoropopliteal arteries. *J Am Coll Cardiol* 2003;41:409-12.
173. Krotz F, Schiele TM, Zahler S, et al. Sustained platelet activation following intracoronary beta irradiation. *Am J Cardiol* 2002;90:1381-4.
174. Derntl M, Syeda B, Beran G, Schukro C, Denk S, Glogar D. Prevention of stent thrombosis following brachytherapy and implantation of drug-eluting stents. *J Interv Cardiol* 2002;15:477-83.
175. Liistro F, Stankovic G, Di Mario C, et al. First clinical experience with a paclitaxel derivate-eluting polymer stent system implantation for in-stent restenosis: immediate and long-term clinical and angiographic outcome. *Circulation* 2002;105:1883-6.
176. Drachman DE, Edelman ER, Seifert P, et al. Neointimal thickening after stent delivery of paclitaxel: change in composition and arrest of growth over six months. *J Am Coll Cardiol* 2000;36:2325-32.
177. Stone GW, Ellis SG, Cox DA, et al. A polymer-based, paclitaxel-eluting stent in patients with coronary artery disease. *N Engl J Med* 2004;350:221-31.