

IMAGES IN CARDIOLOGY

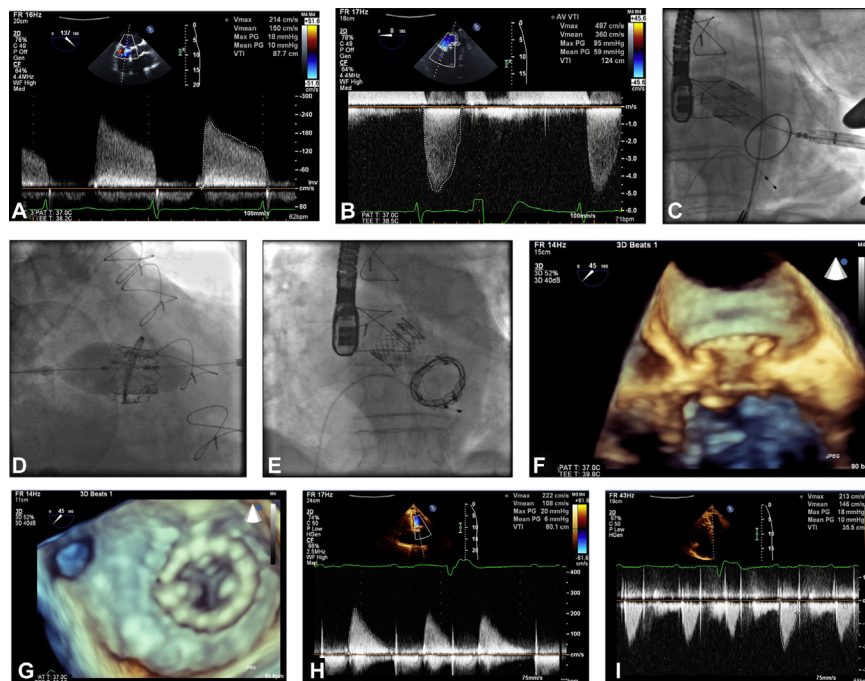
# Simultaneous Transapical Implantation of an Inverted Transcatheter Aortic Valve-in-Ring in the Mitral Position and Transcatheter Aortic Valve Replacement



## First-in-Human Report

Ricardo Ladeiras-Lopes, MD, MSc,\* Luís Vouga, MD,† Pedro Braga, MD,\* Nelson Paulo, MD,† Ana Isabel Azevedo, MD, MSc,\* Paulo Neves, MD,† José Ribeiro, MD,\* Marlene Fonseca, MD,\* Vasco Gama, MD\*

Vila Nova de Gaia, Portugal



From the \*Department of Cardiology, Gaia/Espinho Hospital Centre, Vila Nova de Gaia, Portugal; and the †Department of Cardiothoracic Surgery, Gaia/Espinho Hospital Centre, Vila Nova de Gaia, Portugal.

Manuscript received September 20, 2013; revised manuscript received September 28, 2013, accepted October 1, 2013.

**A** 74-year-old man with a history of surgical mitral ring annuloplasty and evidence of severe mitral (A) and aortic stenosis (B) (Online Video 1) was admitted to our center in New York Heart Association functional class IV refractory to medical therapy. Considering the high surgical risk, we decided to perform a simultaneous implantation of an inverted transcatheter aortic valve (TAV) in the mitral position and transcatheter aortic valve replacement (TAVR) by the transapical approach.

A 26-mm Sapien TAV (Edwards Lifesciences, Irvine, California) was implanted in the aortic position (C, Online Videos 2 and 3) and an inverted 29-mm Sapien TAV was implanted in the mitral position (D, E, Online Videos 4 and 5). Three-dimensional transesophageal echocardiography showed a good procedural result despite 2 moderate mitral paravalvular leaks (F, G).

The patient's functional class improved to class II at the 1-month follow-up (H, I).

We report the first case of simultaneous transapical implantation of an inverted TAV-in-ring in the mitral position and TAVR.